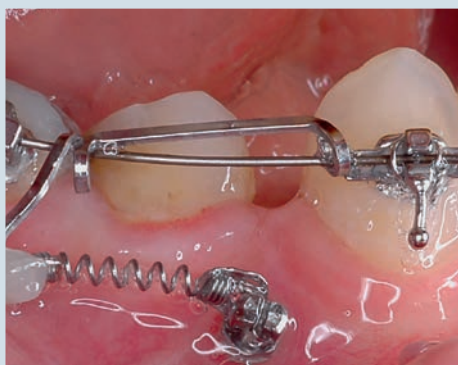

- > A SIX MONTH ISSUE OF THE THESSALIAN STOMATOLOGIC SOCIETY OF GREECE
- > ΕΞΑΜΗΝΙΑΙΑ ΠΕΡΙΟΔΙΚΗ ΕΚΔΟΣΗ ΤΗΣ ΣΤΟΜΑΤΟΛΟΓΙΚΗΣ ΕΤΑΙΡΕΙΑΣ ΘΕΣΣΑΛΙΑΣ



EUROPEAN JOURNAL of DENTAL SCIENCE

ΕΥΡΩΠΑΪΚΟ ΠΕΡΙΟΔΙΚΟ ΤΗΣ ΟΔΟΝΤΙΑΤΡΙΚΗΣ ΕΠΙΣΤΗΜΗΣ



Volume 1, No
Τόμος 1ος, Τεύχος

2012

January - June
Ιανουάριος - Ιούνιος



1

ISSN 2241-1518

EUROPEAN JOURNAL of DENTAL SCIENCE

(Former title: *Odontostomatologic News*)

• Biannual publication of the Thessalian Stomatologic Society of Greece

EDITOR IN CHIEF

Apostolos Tsolakis, DDS, MSD, PhD

ASSOCIATE EDITORS

Ioannis Aetopoulos, DDS, MSD, PhD,
Maxillofacial Surgery

Panagiotis Christou, DDS, PhD,
Orthodontics, Pedodontics and Community Dentistry

Ioannis Kanakis, MSc, PhD,
Oral Biology

Achilleas Katsoupas, DDS,
Prosthodontics

Rodopi Koursoumi, DDS, MSD, PhD,
Oral Surgery & Oral Pathology

Konstantinos Siormpas, DDS,
Dental Implants

Eleftherios-Terry Farmakis, DDS, MSD, PhD,
Endodontics

INTERNATIONAL EDITORIAL BOARD

Eustaquio Araújo, DDS, MSD, PhD, USA

Rolf Behrents, DDS, MSD, PhD, USA

Mark Hans, DDS, MSD, USA

Vladimir Javorka, MUDr, PhD, Slovakia

Ivana Kunijevic, DDS, SERBIA

Franco Magni, DDS, MSD, Italy

Georgios Maroulakos, DDS, MSD, USA

Ioanna Myrtziou, PhD, UK

Juan Martin Palomo, DDS, MSD, USA

Leena Palomo, DSS, MSD, USA

Martin Schimmel, DDS, Switzerland

Peter Stanko, MUDr, PhD, Slovakia

Manish Valiathan, DDS, MSD, USA

ADDRESS for CORRESPONDENCE

Dr Apostolos I. Tsolakis

45, Tsimiski Str., Larisa, GR-412 23 Greece
tel. +30 2410 257688, fax +30 2410 281884
email: apostso@otenet.gr

PRODUCED by

ZANDÉS^{dtP+web}/Print and Electronic Publications
6, Agapinou Str., Thessaloniki, GR-546 21 Greece
tel./fax +30 2310 277119 • email: zandesth@otenet.gr

• Responsibility according to the law: **Dr Apostolos I. Tsolakis**
45, Tsimiski Str., Larisa, 412 23 Greece • tel. +30 2410 257688
fax +30 2410 281884 • email: apostso@otenet.gr

• *The European Journal of Dental Science is an internet free access journal. Website: www.ejods.com.*

ΕΥΡΩΠΑΪΚΟ ΠΕΡΙΟΔΙΚΟ ΤΗΣ ΟΔΟΝΤΙΑΤΡΙΚΗΣ ΕΠΙΣΤΗΜΗΣ

(Προηγούμενος τίτλος: *Οδοντοστοματολογικά Νέα*)

• Εξαμηνιαία περιοδική έκδοση της Στοματολογικής Εταιρείας Θεσσαλίας

ΔΙΕΥΘΥΝΤΗΣ ΣΥΝΤΑΞΗΣ

Απόστολος Τσολάκης, DDS, MSD, PhD

ΑΝΑΠΛΗΡΩΤΕΣ ΔΙΕΥΘΥΝΤΕΣ ΣΥΝΤΑΞΗΣ

Ιωάννης Αετόπουλος, DDS, MSD, PhD,
Γναθοπροσωπική Χειρουργική

Ιωάννης Κανάκης, MSc, PhD,
Βιολογία Στόματος

Αχιλλέας Κατσούπας, DDS,
Προσθετική

Ροδόπη Κουρσούμη, DDS, MSD, PhD,
Παθολογία & Χειρουργική Στόματος

Κωνσταντίνος Σιόρμπας, DDS,
Οδοντικά Εμφυτεύματα

Ελευθέριος-Τέρρυ Φαρμάκης, DDS, MSD, PhD,
Ενδοδοντία

Παναγιώτης Χρίστου, DDS, PhD,

Ορθοδοντική, Παιδοδοντία και Κοινωνική Οδοντιατρική

ΔΙΕΘΝΗΣ ΣΥΝΤΑΚΤΙΚΗ ΕΠΙΤΡΟΠΗ

Eustaquio Araújo, DDS, MSD, PhD, ΗΠΑ

Rolf Behrents, DDS, MSD, PhD, ΗΠΑ

Mark Hans, DDS, MSD, ΗΠΑ

Vladimir Javorka, MUDr, PhD, Σλοβακία

Ivana Kunijevic, DDS, ΣΕΡΒΙΑ

Franco Magni D.D.S., M.S.D., Ιταλία

Γεώργιος Μαρουλάκος, DDS, MSD, ΗΠΑ

Ιωάννα Μύρτζιου, PhD, Ηνωμένο Βασίλειο

Juan Martin Palomo, DDS, MSD, ΗΠΑ

Leena Palomo, DSS, MSD, ΗΠΑ

Martin Schimmel, DDS, Ελβετία

Peter Stanko, MUDr, PhD, Σλοβακία

Manish Valiathan, DDS, MSD, ΗΠΑ

ΔΙΕΥΘΥΝΣΗ ΑΛΛΗΛΟΓΡΑΦΙΑΣ ΕΚΔΟΣΗΣ

Απόστολος Ι. Τσολάκης

Τσιμισκή 45 • 412 23 Λάρισα
τηλ. 2410 257688, fax 2410 281884
email: apostso@otenet.gr

ΤΕΧΝΙΚΗ ΕΠΙΜΕΛΕΙΑ, ΠΑΡΑΓΩΓΗ

ZANΔΕΣ^{dtP+web}/Εκδόσεις Έντυπες και Ηλεκτρονικές
Αγαπηνού 6 • 546 21 Θεσσαλονίκη
τηλ./fax 2310 277119 • email: zandesth@otenet.gr

• Υπεύθυνος, σύμφωνα με το νόμο: **Απόστολος Ι. Τσολάκης**
Τσιμισκή 45 • 412 23 Λάρισα • τηλ. 2410 257688, fax 2410 281884
email: apostso@otenet.gr

• Το Ευρωπαϊκό Περιοδικό της Οδοντιατρικής Επιστήμης αποτελεί διαδικτυακή έκδοση ελεύθερης πρόσβασης. Διαδικτυακός ιστότοπος: www.ejods.com.

ΟΔΗΓΙΕΣ ΠΡΟΣ ΤΟΥΣ ΣΥΓΓΡΑΦΕΙΣ

Το περιοδικό **European Journal Of Dental Science** είναι το επίσημο περιοδικό της Στοματολογικής Εταιρείας Θεσσαλίας και δημοσιεύει ανασκοπήσεις, πρωτότυπες εργασίες, ενδιαφέρουσες περιπτώσεις, κλινικές ή εργαστηριακές μελέτες, ενημερωτικά άρθρα με αντικείμενο την Οδοντοστοματολογία γενικά και τις ειδικότητες ή υποειδικότητες της ειδικότερα, ως και κάθε άρθρο που θα κρίνεται ότι έχει σχέση με την οδοντιατρική επιστήμη. Κάθε εργασία, που υποβάλλεται στο περιοδικό, θα πρέπει να είναι γραμμένη ταυτόχρονα στην αγγλική και ελληνική γλώσσα και να συνοδεύεται από επιστολή, στην οποία θα αναφέρονται: α) η κατηγορία της εργασίας και β) ότι η εργασία δεν έχει δημοσιευθεί, ούτε πρόκειται να δημοσιευθεί σε άλλο ελληνικό ή ξένο περιοδικό.

Διαδικασία αποστολής άρθρου

Το άρθρο υποβάλλεται μέσω email, στο apostso@otenet.gr, σε αρχείο μορφής *.doc, *.docx, *.rtf ή *.odt. Χρήση γραμματοσειρών **OpenType** (π.χ., οι νέες Times New Roman) ή **TrueType**. Το άρθρο δεν πρέπει να υπερβαίνει τις 2500 λέξεις (μέγιστο): συμπεριλαμβάνονται βιβλιογραφία, πίνακες, γραφήματα και παραρτήματα. Μέσω email, ως ξεχωριστά αρχεία, υποβάλλονται και τα εξής:

- 1. Σελίδα τίτλου:** Σε ξεχωριστό αρχείο, το όνομα ή τα ονόματα των συγγραφέων και τα υπόλοιπα στοιχεία τους, καθώς και πλήρη στοιχεία επικοινωνίας μ' έναν από τους συγγραφείς –απαραίτητα, διεύθυνση email.
- 2. Κυρίως Άρθρο:** Σε ξεχωριστό αρχείο, με την εξής σειρά: Σελίδα τίτλου (μόνο ο τίτλος, χωρίς τα στοιχεία των συγγραφέων), Περίληψη (400 λέξεις το μέγιστο), Εισαγωγή, Μέθοδος, Αποτελέσματα, Συζήτηση, Βιβλιογραφία, Πίνακες.
- 3. Βιβλιογραφία:** Αναγράφεται σε ξεχωριστή σελίδα, μετά το τέλος του άρθρου, κατ' αλφαβητική σειρά, σύμφωνα με τους κανόνες του Index Medicus. Δηλαδή, αναγράφονται τα επώνυμα των συγγραφέων, τα αρχικά των ονομάτων τους, ο τίτλος της εργασίας, το όνομα του περιοδικού με τις ανάλογες διεθνείς συντομεύσεις και το έτος δημοσίευσης, π.χ.: Kau CH, Richmond S, Palomo JM, Hans MG. Three dimensional cone beam computerized tomography in orthodontics. Journal of Orthodontics 2005; 32: 282-293.
Αναφορές σε βιβλία, ως εξής: Moorrees C F A. The dentition of the growing child. Harvard University Press, Cambridge 1959.
Στο κείμενο, οι βιβλιογραφικές παραπομπές αναφέρονται με τα ονόματα των συγγραφέων και το έτος δημοσίευσης του άρθρου. Όταν οι συγγραφείς είναι 2, αναφέρονται και τα δύο ονόματα, σε περισσότερους των δύο, αναφέρεται ο πρώτος και ακολουθεί και συν.
- 4. Παραρτήματα:** Τοποθετούνται αμέσως μετά την βιβλιογραφία.
- 5. Πίνακες:** Ακολουθούν τα παραρτήματα. Κάθε πίνακας τοποθετείται σε ξεχωριστή σελίδα και οι επεξηγήσεις του στον τίτλο του. Κάθε πίνακας πρέπει να στέκεται αυτόνομα μέσα στο άρθρο, όμως χωρίς να επαναλαμβάνει δεδομένα, τα οποία αναφέρονται είτε στο κείμενο είτε στο γράφημα.
- 6. Υπότιτλοι Εικόνων / Γραφημάτων / Πινάκων:** Περιλαμβάνουν επεξηγήσεις σχετικά με την εικόνα / φωτογραφία / γράφημα / πίνακα και τοποθετούνται σε ξεχωριστή σελίδα, στο τέλος του άρθρου.
- 7. Γραφήματα / Εικόνες / Φωτογραφίες:** Αποθηκεύονται ως ξεχωριστά αρχεία, μία εικόνα ανά σελίδα. Υποβάλλονται ηλεκτρονικά, σε αρχεία μορφής *.psd, *.tiff, *.jpeg, *.pdf, *.eps. Ελάχιστη ανάλυση τα 300 dpi για έγχρωμες εικόνες ή μονόχρωμες και 600 dpi για γραμμικά σχέδια. Η ελάχιστη ανάλυση αναφέρεται στο τελικό μέγεθος της εικόνας στη σελίδα.
- 8. Δικαιώματα:** Απαραίτητη προϋπόθεση, για τη δημοσίευση ενός άρθρου, είναι η διατύπωση και υπογραφή, από τους συγγραφείς, *Δήλωσης Μεταβίβασης Δικαιωμάτων*. Αυτή αποστέλλεται (με fax) στον συντάκτη, κατά τη στιγμή της υποβολής του άρθρου προς κρίση.

Συμπληρωματικά

- Τα άρθρα υποβάλλονται προς κρίση, υπό την προϋπόθεση ότι δεν έχουν υποβληθεί προς δημοσίευση αλλού, είτε μερικώς είτε ολικώς, και σε οποιαδήποτε γλώσσα. Στην περίπτωση αυτή, ακυρώνεται η διαδικασία κρίσης του άρθρου κι αυτό επιστρέφεται στους συγγραφείς.
- Άρθρο που υποβάλλεται χωρίς να τηρεί τις παραπάνω προϋποθέσεις, δεν γίνεται δεκτό από τη σύνταξη του περιοδικού. Το περιοδικό μας δέχεται άρθρα που αφορούν όλο το φάσμα της οδοντιατρικής επιστήμης.
- Οι εργασίες, που δημοσιεύονται, αποτελούν πνευματική ιδιοκτησία του συγγραφέα και του περιοδικού. Η δημοσίευση μιας εργασίας δεν συνεπάγεται και αποδοχή των απόψεων των συγγραφέων από πλευράς περιοδικού.
- Εργασίες και επιστολές αποστέλλονται στη διεύθυνση:

Dr Apostolos Tsolakis

Tsimiski 45, Larisa 412 23, Greece

tel. +30 2410 257688, fax +30 2410 281884,

email: apostso@otenet.gr

INSTRUCTIONS FOR AUTHORS

European Journal Of Dental Science is the official journal of the Stomatological Society of Thessaly and publishes original articles, review articles, reports of interesting clinical cases, clinical or laboratory studies, editorials, letters to the editor and any article related to Odontostomatology.

Manuscripts may be written in English and should include a summary in Greek. Greek summaries of our foreign authors will be prepared by the editorial board. Articles should be submitted through e-mail. Manuscripts must be typewritten with double spaced lines and there should be wide margins (about 2.5 cm).

The **first page** of the manuscript should include the title of the article, full name(s) of the author(s), academic degrees, and institutional affiliations and positions. The second page should have only the title of the paper. The last page of the manuscript should include the corresponding author's address, business and home telephone numbers, fax numbers, and e-mail address.

Any **article** must include 1. Abstract of 150 words or less 2. Introduction indicating the purpose of the study 3. Description of the methods and materials used 4. Results 5. Discussion 6. Conclusions and 7. References. A summary in English or Greek of 400 words or less must be provided at the end.

References should be written in a separate page and in alphabetic order. References in the text should be quoted by the author's name(s) and the year of publication. In the case of two authors both names should be stated. If there are more than two authors only the first author plus et al. is used. References to papers must be given as follows: Kau CH, Richmond S, Palomo JM, Hans MG. Three dimensional cone beam computerized tomography in orthodontics. Journal of Orthodontics 2005; 32: 282-293. References to books must be given as follows: Moorrees C F A. The dentition of the growing child. Harvard University Press, Cambridge 1959.

Illustrations: All illustrations including tables should be cited consecutively in the text. **Figures** should be saved as separate high-resolution image files without their captions (captions should be included with the text of the article). Minimum resolutions are 300 d.p.i. for colour or tone images, and 600 d.p.i. for line drawings. The preferred format is *.psd, *.tiff, *.jpeg, *.pdf, *.eps.. Font-related problems can be avoided by using standard fonts such as Times Roman and Helvetica. Wherever possible, figures should be submitted in their desired final size, to fit the width of a single column of text (76 mm) or a double column of text (160 mm), and to a maximum height of 160 mm, thereby allowing space for the figure caption. Any lettering should be approximately 2 mm in height and should be in proportion to the overall dimensions of the figure.

Photographs should be of sufficiently high quality with respect to detail, contrast and fineness of grain to withstand the inevitable loss of contrast and detail inherent in the printing process. Line drawings should have clear and sharp lines that are a minimum of 1 point in thickness. Shading used on line drawings should be clear and distinctive; shades of grey will not reproduce well and small patches of white on an otherwise black background are likely to be lost on reproduction. Symbols used in figures should be limited to standard open and closed symbols (circles, squares, triangles and diamonds). Symbols cannot be generated in the legend and should be described rather than indicated by a symbol. Figures and legends should be intelligible without reading the text of the manuscript. Photographs of people must be accompanied by a written consent. Failure to do so will result in the blacking out of the eyes to avoid recognition. Please note that it is not sufficient to use microscope images/slides at a different magnification and allege that they are different images.

Proofs: Authors will receive a PDF file of the complete paper by email. In the interest of speed, corrections must be returned within 48 hours. No major changes are permissible at this stage and alterations should be restricted to correction of typographical errors. Please check text and figures very carefully. Corrections will be done at the expense of the authors.

Copyright: Authors submitting manuscripts do so with the understanding that if their work is accepted for publication, copyright of the article, including the right to reproduce the article in all forms and media, shall be assigned exclusively to European Journal Of Dental Science. No reasonable request by authors for permission to reproduce their contribution will be refused.

Authors are reminded that it is their responsibility to comply with copyright laws. It is essential to ensure that no parts of the text or the illustrations have or are due to appear in other journals, without prior permission from the copyright holder. Manuscripts for publication should be submitted via email to: apostso@otenet.gr Responsible for the publication:

Dr Apostolos Tsolakis 45, Tsimiski Str., Larisa, GR-412 23 Greece

Tel. +30 2410 257688, fax +30 2410 281884 • email: apostso@otenet.gr



CONTENTS

Peri-implantitis: the disease is eventually well documented, the efficacy of current treatment is not..... 5

Spyridon Vassilopoylos, Nikolaos Roussos

Orthodontic Mini-Implants: Answers to common questions..... 18

Konstantina Syrrakou, Demetrios Halazonetis

Choice criteria and evolution of dental implants abutments..... 28

Konstantinos S. Pallis, Spyridon A. Doukoudakis

Congenitally missing upper laterals. Clinical considerations –Part I: Orthodontic space closure..... 39

Panagiotis Prevezanos, Marina Karamolegkou, Martin Schimmel, Panagiotis Christou

Congenitally missing upper laterals. Clinical considerations –Part II: Prosthodontic options..... 45

Panagiotis Prevezanos, Marina Karamolegkou, Martin Schimmel, Garavaglia Giovanni, Panagiotis Christou

EUROPEAN JOURNAL of DENTAL SCIENCE

(Former title: *Odontostomatologic News*)

■ Biannual publication of the Thessalian Stomatologic Society of Greece

ΕΥΡΩΠΑΪΚΟ ΠΕΡΙΟΔΙΚΟ ΤΗΣ ΟΔΟΝΤΙΑΤΡΙΚΗΣ ΕΠΙΣΤΗΜΗΣ

(Προηγούμενος τίτλος: *Οδοντοστοματολογικά Νέα*)

■ Εξαμηνιαία περιοδική έκδοση της Στοματολογικής Εταιρείας Θεσσαλίας

Editor's Message

Dear Colleagues,

The *European Journal of Dental Science* is the official biannual, open and free access publication of the Hellenic Stomatologic Society of Thessaly, formerly known as "Odontostomatologic News". It is a multidisciplinary peer-reviewed dental journal, publishing articles in the field of dentistry.

The first issue of each year will be circulated the last day of June and the second issue will be circulated the last day of December of each year, via our website. The Editorial Board accepts articles that meet the rules of evidence-based dentistry and also provide a practical use for the general dentists and/or specialists in dentistry. Furthermore, the Editorial Board is looking for immediate scientific consideration of all articles from the journal's reviewers and welcomes all comments and suggestions of our colleagues.

We wish to assure our colleagues that, in selecting and evaluating papers for publication in our journal, we follow strict international protocols. We are expecting that our scientific advisory board of reviewers will soon grow and we are committed to presenting the international dental community with high-quality, evidence-based clinical and research papers.

Finally, we take the occasion to invite colleagues from all over the world to consider submitting some of their next scientific studies, clinical cases or critical reviews for publication in the *European Journal of Dental Science*.

Sincerely yours,

Apostolos Tsolakis, D.D.S, M.S.D, Ph.D.

Editor in Chief.

Μήνυμα της Σύνταξης

Αγαπητοί Συνάδελφοι,

Το *European Journal of Dental Science* είναι εξαμηνιαίο επιστημονικό περιοδικό και με ελεύθερη πρόσβαση, μέσω του διαδικτύου. Αποτελεί συνέχεια του περιοδικού «Οδοντοστοματολογικά Νέα» της Στοματολογικής Εταιρείας Θεσσαλίας και δημοσιεύει ανασκοπήσεις, πρωτότυπες εργασίες, ενδιαφέρουσες περιπτώσεις, κλινικές ή εργαστηριακές μελέτες, ενημερωτικά άρθρα με αντικείμενο την Οδοντιατρική επιστήμη και τις ειδικότητες ή υποειδικότητές της.

Το πρώτο τεύχος κάθε έτους κυκλοφορεί την τελευταία μέρα του Ιουνίου κάθε έτους και το δεύτερο τεύχος κυκλοφορεί στο τέλος Δεκεμβρίου του ίδιου έτους, μέσω του ιστοτόπου του περιοδικού. Κύριο μέλημα της συντακτικής επιτροπής είναι η δημοσίευση άρθρων που έχουν επιστημονική αξιοπιστία αλλά και πρακτική χρησιμότητα για τον γενικό οδοντίατρο. Η συντακτική επιτροπή αξιολογεί, με επιστημονικά κριτήρια, όλα τα υποβαλλόμενα άρθρα, αμέσως προωθώντας αυτά στους κριτές του περιοδικού. Επιπλέον, με ιδιαίτερη προσοχή αξιολογεί τις παρατηρήσεις κάθε συναδέλφου.

Θέλουμε να σας διαβεβαιώσουμε πως, για την επιλογή και την κρίση των άρθρων προς δημοσίευση, ακολουθούνται, αυστηρά, όλοι οι διεθνώς καθιερωμένοι κανόνες αξιολόγησης επιστημονικών εργασιών. Πιστεύουμε πως σύντομα θα διευρυνθεί ακόμα περισσότερο η ομάδα των κριτών του περιοδικού μας και πως θα είμαστε, και στο μέλλον, σε θέση να παρουσιάζουμε τεκμηριωμένες εργασίες υψηλού κλινικού και επιστημονικού επιπέδου. Τέλος, θα θέλαμε να προσκαλέσουμε τους συναδέλφους μας, από όλο τον κόσμο, να υποβάλλουν κάποιες από τις επόμενες εργασίες τους στο περιοδικό μας.

Δρ Απόστολος Τσολάκης

Επίκουρος Καθηγητής Ορθοδοντικής ΕΚΠΑ
Διευθυντής Σύνταξης

Peri-implantitis: the disease is eventually well documented, the efficacy of current treatment is not.

Spyridon Vassilopoulos¹, Nikolaos Roussos²

SUMMARY

Dental implants have been used for decades in daily clinical practice. They offer innovative solutions when conventional prosthetic rehabilitation (fixed or removable) is impossible. However, health maintenance of soft and hard peri-implant tissues should not be taken as granted. In addition, the loss of a functional implant is mainly a result of the inflammatory destruction of the peri-implant tissues. Peri-implant diseases include the peri-implant mucositis (affecting only the soft peri-implant tissues) and the peri-implantitis (extensive inflammation of both soft and hard tissue, resulting in loss of the supporting bone). Scientists have been already concerned by the prevalence of peri-implant diseases that recent epidemiological studies have indicated. At the same time peri-implant diseases share common features with periodontal diseases regarding the pathogenesis, the symptomatology and the development of tissue destruction. Nevertheless, when it comes to peri-implant diseases, the effectiveness of therapeutic modalities that are applied in periodontology is still not guaranteed. This is probably a result of the metallic implant surface and the special configuration of the peri-implant tissues, taking into serious consideration the absence of the periodontal ligament.

The present study is a review of the literature on the epidemiology, pathogenesis, risk factors, diagnosis and the treatment of peri-implant diseases. Special focus is given on all the available diagnostic methods so that the clinician will be able to recognize peri-implant diseases on early stage. Last but not least, extensive analysis and discussion regarding the non surgical and surgical therapeutic modalities and their predictability is presented in the current review.

► **Key-Words:** peri-implant diseases, peri-implantitis, peri-implant mucositis.

INTRODUCTION

Implantology is eventually well established in the daily clinical practice. In the recent years the evolution of both science and implant industry have made the treatment outcomes of implant therapy even more predictable. Implant design and implant surface have been improved and surgical protocols have been simplified. As a result, the provision of implant therapy

have become more easy and more tempting for the general dentist.

A surviving implant is that which remains functional in the oral cavity. On the contrary, a successful implant is that which fulfills particular requirements associated with peri-implant tissues. Implant survival in the general population is impressively high: 95.4% after 5 years and 92.8% after 10 years (Pjetursson et al 2004). Nevertheless, complications still occur. Only implant success under specific criteria expresses safely the clinical course of dental implants. There is no general consensus about the implant success criteria yet. Health of peri-implant tissues, particularly the height of peri-implant bone, is considered of many investi-

¹Lecturer of Periodontology

²Resident of Periodontology (Post-graduate student)

Correspondence to Spyros Vassilopoulos
tel. 210 6925960, 6936925960, email: spvas@me.com

Submitted, January 2012; revised and accepted, March 2012.

gators as significant parameters of implant success. Inflammatory processes of these tissues are described as peri-implant diseases.

Peri-implant diseases, by analogy to periodontal, include *peri-implant mucositis* which corresponds to gingivitis, and *peri-implantitis* which corresponds to periodontitis. These terms were firstly introduced into the 1st European Workshop of Periodontology (Albrektsson, Isidor, 1993). **Peri-implant mucositis** was defined as a reversible inflammation of the soft tissues surrounding implants in function. **Peri-implantitis** was defined as an inflammation of both peri-implant soft and hard tissues resulting in loss of peri-implant bone of a functioning implant.

These definitions were reevaluated in last European Workshop of Periodontology (Zitzmann and Berglundh 2008). The term “reversible” was removed of the definition of peri-implant mucositis because it was implying that peri-implantitis is not reversible, hence, impossible to be treated. In addition, it was clarified that bone loss at peri-implantitis is associated with implants during function, after osseointegration is complete, and is not associated with the normal bone remodeling that occurs immediately after implant installation (Zitzmann and Berglundh 2008).

Peri-implant mucositis and peri-implantitis present different histological features at human biopsies. In peri-implant mucositis the peri-implant lesion was dominated by T cells and was restricted apically to the barrier epithelium (Zitzmann et al 2001). In peri-implantitis the lesion extended apical to the pocket epithelium and contained large proportions of plasma cells, lymphocytes, PMN's and macrophages (Gualini and Berglundh 2003, Berglundh και συν. 2004).

A more rare pathologic entity in the literature is called periapical or retrograde peri-implantitis. This infection of the apical portion of the implant was first described by Quirynen et al (2005) as a “periapical” lesion without symptoms, which is developed early after the installation of the implant without disturbing the bone-implant interface.

EPIDEMIOLOGY

Epidemiological data about peri-implant diseases vary, because investigators utilize different definition criteria of peri-implant diseases. More specifically, Ferreira et al (2006) stated that the diagnosis of peri-implantitis requires peri-implant pocket depth ≥ 5 mm, bleeding on probing and vertical bone loss. Similar criteria were used by Karoussis et al (2004a) such as peri-implant pocket depth ≥ 5 mm, bleeding on probing or

pus and radiographic bone loss. In addition, Berglundh et al (2002) suggest that peri-implant pocket depth > 6 mm and bone loss or attachment loss ≥ 2.5 mm are necessary criteria for the diagnosis of peri-implantitis.

Useful data regarding the prevalence of peri-implant diseases are presented in the review of Zitzmann and Berglundh (2008). They analyzed cross-sectional and longitudinal studies including ≥ 50 implant-treated subjects exhibiting a function time ≥ 5 years. Only two studies met the inclusion criteria. Peri-implant mucositis occurred in 80% of the subjects and in 50% of the implant sites. Peri-implantitis was identified in 26% and $\geq 56\%$ in subjects and in 12% and 43% of implant sites respectively. Furthermore, taking into account that epidemiological studies about periodontal diseases were carried out in much larger population samples and teeth function for decades, it is recommended to carry out cross-sectional studies with much larger samples and prolonged follow up in order to draw more safe and more accurate conclusions about the epidemiology of peri-implant diseases.

Finally, the data about the epidemiology of retrograde peri-implantitis in the literature are rare. In a study of 539 implants, retrograde peri-implantitis occurred in 1.6% of the maxillary implants and in 2.7% of the mandibular implants (Quirynen et al 2005).

PATHOGENESIS

The configuration of soft and hard tissues surrounding both implants and teeth present similarities. Meanwhile, periodontal and peri-implant diseases share common clinical features. Experimental and clinical studies have shown as a common etiologic factor of periodontitis and peri-implantitis the deposition of plaque on teeth and on implant surface respectively. The evidence supporting that microorganisms are the major causative factor of peri-implantitis have been categorized by Mombelli and Lang (1998) into five categories:

- a) experiments in humans showing that deposition of plaque can induce peri-implant mucositis,
- b) the demonstration of distinct quantitative and qualitative differences in the microflora associated with successful and failing implants,
- c) placement of plaque retentive ligatures in animals leading to peri-implantitis,
- d) antimicrobial therapy improving the clinical status of peri-implantitis patients,
- e) the level of oral hygiene has an impact on the long-term success of implant therapy.

In addition, peri-implant tissues exhibit lower resistance against microorganisms when compared to periodontal tissues (Lindhe et al 1992, Marinello et al 1995, Ericsson et al 1996). More specifically, Lindhe et al (1992) noticed significant differences in the size and the extension of inflammatory lesions between peri-implant and periodontal tissues. Furthermore, periodontal inflammation was restricted in the connective tissue, whereas the peri-implant inflammation was extended in to the adjacent alveolar bone.

Factors that are implicated in the etiology of retrograde peri-implantitis are:

- a) microbial contamination during implant installation,
- b) early loading,
- c) endodontic pathology, either remaining after tooth extraction or present around neighboring teeth (Dahlin et al. 2009).

RISK FACTORS-INDICATORS

Factors that have been implicated to favor the development of peri-implantitis are:

- a) history of periodontitis (Karoussis et al. 2007),
- b) diabetes (Ferreira et al. 2006),
- c) genetic traits (Laine et al. 2006),
- d) smoking (Strietzel et al. 2007),
- e) alcohol consumption (Galindo-Moreno et al. 2005),
- f) oral hygiene level (Ferreira et al. 2006),
- g) presence of keratinized mucosa (Roos-Jansåker et al. 2006b),
- h) implant surface characteristics (Wennström et al. 2004).

Nevertheless, there is n't sufficient documentation to confirm a strong association of all of abovementioned factors with the development of peri-implantitis. Heitz-Mayfield (2008) analyzed data from prospective and cross-sectional studies and from systematic reviews as well. The investigator noticed a strong association between peri-implantitis and low level of oral hygiene, history of periodontitis and smoking. In general, rehabilitation with dental implants of partial edentulism of patients with history of periodontitis requires extremely caution, considering that periodontal therapy results in control of inflammation but has no effect on host's response (Aloufi et al 2009). Further-

more, the three dimensional bone loss occurring in advanced periodontal diseases causes limitations on options regarding the implant length and diameter.

A third parameter that must be taken into consideration is the periodontopathogens dissemination from natural teeth to dental implants. However, data about the relationship between peri-implantitis and diabetes or alcohol consumption were founded to be insufficient (Heitz-Mayfield 2008). In addition, genetic traits and implant surface couldn't be associated with peri-implantitis, as the evidence from various studies was contradictory (Heitz-Mayfield 2008).

Some fail to establish an association between clinical parameters of peri-implantitis and gene polymorphisms of IL-1 (Lachman et al 2007), whereas others report a significant synergistic effect of IL-1 genotype and smoking peri-implant bone loss (Feloutzis et al 2003). Laine et al (2006) reported an association between peri-implantitis and specific alleles of IL-1. While in one study a similar peri-implant bone loss both on smooth and moderate rough surfaces was demonstrated (Wennström et al 2004), in another study peri-implantitis was more frequent at implants with rough surfaces comparing with implants with smooth surfaces (Astrand et al 2004).

Data focus also on some other factors affecting peri-implant bone loss. Tabanella et al (2009) report greatest amount of horizontal bone loss on implants supporting over dentures, followed by implants supporting fixed partial dentures and hybrid dentures. This is probably caused by the unfavorable design which permits mechanical forces distribution more laterally than axially. Useful evidence is provided by Fransson et al (2009) who analyzed patients' files and intraoral radiographs from 182 subjects (1070 implants). 419 implants exhibited peri-implantitis-associated bone loss. The implants were grouped into four categories (upper posterior, upper front, lower posterior, lower front). In addition, an implants was defined as a "mid" abutment if another implant within the reconstruction was positioned in both it's mesial and distal aspect. In another cases the implant was classified as an "end" abutment. The frequency of bone loss associated with peri-implantitis was higher among implants placed in the lower front positions than in other regions. Furthermore, "end" implants were not associated with increased risk of bone loss.

DIAGNOSIS

Taking into serious consideration the abovementioned risk factors-indicators, the intervals between

recall visits are determined. During these recall visits peri-implant tissues are assessed by diagnostic methods which are applied for the diagnosis of periodontal diseases as well. First, informations, which are not pathognomonic, are obtained from the patient who could report some subjective symptoms (e.g. pain). Afterwards, signs of inflammation (edema and erythema) are detected by simple observation (fig. 1). Very useful are the modified by Mombelli (1987) plaque index and gingival index (table 1). Furthermore, peri-implant pocket depth, bleeding on probing, suppuration and mobility are assessed (Heitz-Mayfield 2008). Radiographic examination is also recommended (Heitz-Mayfield 2008).

Finally, peri-implant crevicular fluid analysis and microbial tests could contribute to the final diagnosis (Heitz-Mayfield 2008).

PROBING OF PERI-IMPLANT POCKET DEPTH AND PERI-IMPLANT "ATTACHMENT" LEVEL.

It must be clarified that in peri-implant tissues there is not a true connective tissue attachment, like in natural teeth where Sharpey's fibers penetrate the root cementum. Peri-implant connective tissue which covers the alveolar margin, is in very close contact with the implant surface by a fiber's net (parallel to the implant surface) without being attached (Behneke 2004). This tissue structure resists to the probe penetration under clinical health. However, it has been reported that as the severity of peri-implant inflammation increases, the penetration of the probe also increases, reaching 1.6 mm within peri-implant connective tissue in the case of peri-implantitis (Lang et al 1994, Shou et al 2002). In addition, in mild inflammation peri-implant connective tissue seems more vulnerable in probe penetration than the connective tissue surrounding natural teeth (Heitz-Mayfield 2008). Hence, the probing force must be determined. Probing force of 0.25N is recommended, as it has been documented that it doesn't penetrate or cause damage to peri-implant tissue (Mombelli et al 1997, Etter et al 2002).

Peri-implant pocket depth is defined as the distance from peri-implant soft tissue margin to the bottom of the peri-implant pocket (Karoussis et al 2009). Peri-implant "attachment" level is defined as the distance from a fixed reference point (e.g. implant neck) to the bottom of the peri-implant pocket (Karoussis et al 2009). Peri-implant pocket depth ≥ 5 mm is considered as pathognomonic for peri-implantitis by Ferreira et al (2006) and by Karoussis et al (2004a), whereas > 6 mm by Berglundh et al (2002).

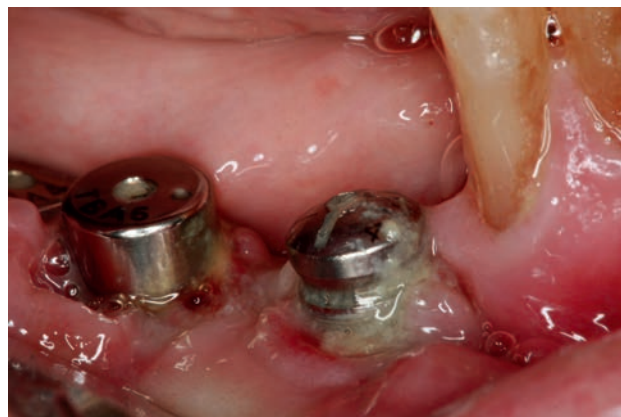

Fig. 1. Characteristic clinical presentation of peri-implant infection.

Difficulties during probing of peri-implant pocket are associated with the configuration of the suprastructure or with the implant surface. As a result, clinician must interpret the results with caution. In addition, one specific measurement is not definitive for the diagnosis of peri-implantitis. For instance, greater measurements of peri-implant pocket depth are provided when the implant is deliberately installed more apically for esthetic reasons or when the peri-implant soft tissues are edematous and hyperplastic. The diagnosis of peri-implantitis requires sequential measurements at different time points certifying the progressive increase of peri-implant pocket depth. Hence, it is of great importance the initial peri-implant pocket depth measurement immediately after completion of osseointegration and biologic width establishment, in order to serve as reference point of future measurements.

Nevertheless, assessment of peri-implant "attachment" level is more reliable method, because peri-implantitis may be accompanied by recession of peri-implant soft tissues margin. In addition, it has been documented that peri-implant "attachment" level at 1, 3 and 6 months after the installation of the final restoration serve as prognostic factor for radiographic peri-implant bone loss after 24 months (Bragger et al 1996).

BLEEDING ON PROBING

Presence of bleeding on gentle probing (0.25N) is a useful parameter for diagnosis of peri-implant soft tissue inflammation. However, this method does not contribute to differential diagnosis between peri-implant mucositis and peri-implantitis. In experimental study is reported absence of bleeding on probing in healthy peri-implant tissues (specificity 100%) (Lang et al 1994). The same research group has detected bleed-

Grade	Modified plaque index (mPI)	Modified gingival index (mBI)
0	Absence of plaque	Absence of bleeding on probing buccally and lingually in 1 mm depth
1	Detected plaque by probing the machined surface of the implant	Spots of bleeding
2	Clinical visible plaque	Continued blood line on the peri-implant mucosal margin
3	Abundance of calculus	Intense or spontaneous bleeding

Table 1. Modified by Mombelli plaque and gingival index for peri-implant tissues.

ing on probing on 67% of peri-implant mucositis cases and on 91% of peri-implantitis cases. Luterbacher et al (2000) showed that any site bleeding at more than half of the recall visits over a 2 year period had disease progression.

Thus, the positive predictive value (of $\geq 50\%$ bleeding on probing) was 100%. It is noteworthy that the corresponding positive predictive value of bleeding on probing for teeth is much lower (40%) (Heitz-Mayfield 2008). The negative predictive value of bleeding on probing, to indicate peri-implant stability, varied between 50% and 64% for a threshold bleeding on probing frequency of $> 20\%$ (Luterbacher et al 2000). Thus, bleeding on probing is a useful clinical parameter providing reliable informations for both the diagnosis and prognosis of peri-implant diseases. Similarly, suppuration upon probing which is more rare clinical sign constitutes a definitive indication of infection and inflammatory destruction (Heitz-Mayfield 2008).

MOBILITY AND PERCUSSION TESTS

Implant mobility indicates lack of osseointegration. Therefore, implant removal is recommended when mobility is detected (Heitz-Mayfield 2008). Thus, implant mobility does not contribute to early diagnosis of peri-implant diseases. One the other hand, absence of mobility doesn't provide information about osseous support of the implant and does not exclude peri-implant lesion in progress, as the presence of a residual bone to implant contact is adequate to immobilize the implant. In addition, it has been reported that well osseointegrated implants produce a distinctive acute sound in response to percussion (Salvi et al 1999).

Conversely, implants surrounded by connective tissue produce a dull sound, which is emerged prior to radiographic findings associated with implant loss (Salvi et al. 1999). Although, percussion seems to pro-

vide significant information, it is relatively subjective and therefore needs further documentation to certify the reliability for the diagnosis of peri-implantitis.

RADIOGRAPHIC EXAMINATION

Radiographic examination methods which are applied on implants during maintenance include:

- intraoral "periapical" radiography* according to the paralleling technique, which apart from distal and mesial peri-implant bone does not depict the buccal and palatal-lingual peri-implant bone (Heitz-Mayfield 2008, Fourmoussis and Brägger 1999),
- panoramic radiography* which allows the entire maxilla and mandible to be visualized but it is characterized by reduced resolution and low sensitivity in the detection of early bone changes (Heitz-Mayfield 2008, Fourmoussis and Brägger 1999),
- digital subtraction radiography* which improves the diagnostic accuracy as it allows detection of small changes in bone density (Heitz-Mayfield 2008, Fourmoussis and Brägger 1999),
- computer tomography and cone beam volume imaging* offer a 3-D depiction of the osseous structures but have showed a slight artifact immediately adjacent to the implant (Heitz-Mayfield 2008).

It has been reported that radiographic examination, initially, must be performed at 6 and 12 months after completion of the restoration. Afterwards, in clinically healthy peri-implant tissues an annual radiographic examination is recommended (Gröndahl 2003). In total absence of clinical signs and symptoms the intervals between radiographic examinations could be increased to 2 or to 3 years (Gröndahl 2003). In the advent of clinical signs and symptoms, an immediate radiographic assessment of peri-implant bone level should be performed, as a positive association of peri-

implant pocket depth and peri-implant attachment level with the radiographic peri-implant bone loss has been reported (Brägger et al 1996).

Implants placed in the same patients cannot be regarded as independent with respect to marginal bone loss. Consequently, the “one implant per patient radiographic examination technique” has been introduced by Mau (1993) as a simple method to decrease the radiation dose. However, this method is not popular and needs further investigation.

The aim of the radiographic examination is the detection peri-implant bone loss which is not compatible with implant success (Fig. 2). The most commonly used criteria of success are those suggested by Albrektsson and Isidor (1994) who stated that a bone loss of 1.5 mm during first year of function is not a sign of implant failure but a result of the normal bone remodeling. Furthermore the annual bone loss of 0.2 mm after the first year of function was also regarded as normal process (Albrektsson and Isidor 1994). Duyck and Naert (1998) asserted that a mean bone loss of 0.9 to 1.6mm during the first year followed by an annual bone loss within 0.01 to 0.2mm could be within acceptable limits. Wennström and Palmer (1999) claimed that a bone loss < 2 mm during the first 5 years should be required for an implant to consider successful. As baseline should be considered the radiographic examination immediately after restoration (Wennström and Palmer 1999). It is noteworthy that peri-implant bone level alterations of 0.2 mm cannot be detected radiographically (Wennström and Palmer 1999). Finally, an additional limitation of radiographic examination is the lower sensitivity in detection of bone to implant contact loss, compromising the diagnostic and prognostic value of this method.

MICROBIAL TESTING

The microbial qualitative and quantitative diagnostic tests that have been proposed include bacterial culture, dark field or phase contrast microscopy, monoclonal antibody, DNA probes, ELISA method and polymerase chain reaction. However, these methods can't be incorporated in daily clinical practice due to the additional required cost, time and equipment. Nevertheless, the presence of specific bacteria during recall visits enhance the prognostic value of bleeding on probing for identifying disease progression at implants (Luterbacher et al 2000). In addition, data derived from microbial tests contribute to the right choice of the antimicrobial drug and to the treatment outcome assessment (Behneke 2004).

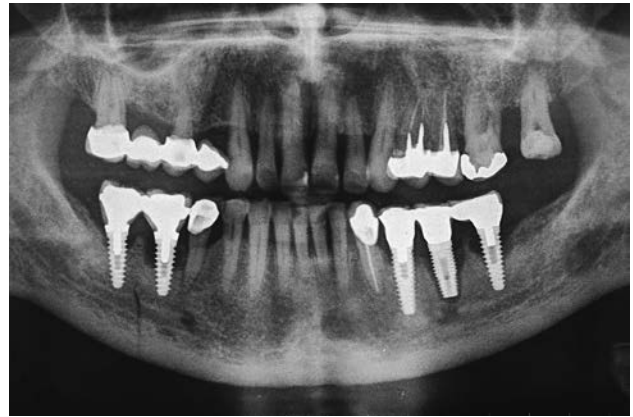

Fig. 2. Extended peri-implant bone loss as it is shown radiographically.

PERI-IMPLANT CREVICULAR FLUID AND SALIVA ANALYSIS

Recent studies have focused on the possible association of biochemical markers (cytokines, enzymes and proteases) present in peri-implant crevicular fluid or in saliva with clinical parameters of healthy or inflamed peri-implant tissues (Heitz-Mayfield 2008). Although, data indicates a potential for diagnostic test, prospective longitudinal studies are required to correlate disease progression with biochemical markers, so that they can be used for detecting reversible changes prior of tissue destruction establishment (Heitz-Mayfield 2008).

DIAGNOSIS OF RETROGRADE PERI-IMPLANTITIS

Clinical findings of retrograde peri-implantitis include pain, tenderness, redness, swelling and sometimes the presence of a fistulous tract (Dahlin et al 2009). Also, with “periapical” radiography a radiolucency in the “apical” portion of the implant can be visualized (Dahlin et al 2009). It should be distinguished from clinically asymptomatic “periapical” radiolucency, which is usually caused by implants that are shorter than the drilled site or by heat-induced aseptic bone necrosis (Quirynen et al 2005, McAllister et al 1992, Reiser et al 1995).

THERAPY

The aims of the therapy of peri-implantitis are:

- a) resolution of inflammation of peri-implant tissues in order to avoid progression of tissue destruction,
- b) regeneration, when possible, of lost peri-implant tissues.

Non surgical and surgical therapeutic techniques with various efficacies are subjected to intense investi-

gation (Renvert et al 2008, Kotsovilis et al 2008, Claffey et al 2008, Renvert et al 2009).

A. Non surgical methods.

A.1. Mechanical therapy alone.

Implant surface debridement is performed by plastic, carbon fibre and titanium scalers and curettes and by air-powder abrasive system (Fourmouzis 2003). This treatment modality seems to be effective in the case of peri-implant mucositis (Renvert et al 2008). Specifically Maximo et al (2009) performed mechanical therapy alone (Teflon curettes) to treat peri-implant mucositis, and they observed improved clinical parameters (plaque index, bleeding on probing, peri-implant pocket depth and peri-implant attachment level) after 3 months. However, the limited number of implant (12) and the duration (3 months) of the study don't allow drawing safe conclusions.

The efficacy of the mechanical therapy alone in the case of peri-implantitis was assessed in a randomized clinical trial (Karring et al 2005). This treatment modality was found to be insufficient and no reduction in peri-implant pocket depth was observed (Karring et al 2005). Therefore, it was supported that non surgical mechanical therapy is much less effective in the case of peri-implantitis (Renvert et al 2008, Kotsovilis et al 2008). In addition, limitations regarding the access of the implant surface due to the configuration of the suprastructure and the efficacy of the previous mentioned modified curettes, compromise the treatment outcome. Thus, a number of adjunctive therapeutic methods to improve the treatment outcome are recommended.

A.2. Mechanical therapy in conjunction with antiseptic agents.

Randomized clinical trial from Felo et al (1997) shows that local irrigation with chlorhexidine 0.06% was more beneficial (statistically significant greater reduction of plaque and bleeding index) in the treatment of peri-implant mucositis than the use of chlorhexidine 0.12% as daily mouth rinse. Conversely, another randomized clinical trial showed that the use of chlorhexidine (gel 0.12% and local irrigation 0.12%) didn't enhance the efficacy of mechanical treatment of peri-implant mucositis (Porras et al 2002). In addition, the monthly application of phosphoric acid gel 35% in the peri-implant sulci for 1 min as adjunctive method of mechanical treatment of peri-implant mucositis showed a favorable effect on clinical parameters and

reduction of CFU's (Strooker et al 1998). However, evidence have showed that irrigation with chlorhexidine 0.2% as an adjunctive modality of mechanical treatment of peri-implantitis may lead to statistically significant improvements in bleeding on probing, peri-implant pocket depth and peri-implant "attachment" level at 6 months compared with baseline (Schwarz et al 2005, Schwarz et al 2006a).

It is a noteworthy finding that moderate lesions (initial peri-implant pocket depth 4-6 mm) showed an increase in the mean peri-implant pocket depth and peri-implant "attachment" level from baseline to 12 months, whereas in advanced lesions (initial pocket depth > 7 mm) these parameters decreased (Schwarz et al 2006a). Furthermore this treatment modality was regarded as incomplete due to the presence of residual peri-implant pockets (mean value 4.8 ± 1.4 mm) 6 months after therapy.

A.3. Mechanical therapy in conjunction with antibiotics.

In the therapy of peri-implant diseases antibiotics may be delivered via the systemic route or by application into the peri-implant pocket. Tetracycline fibers have been used in the treatment of peri-implant mucositis, without additional therapeutic value on mechanical treatment (Renvert et al 2008). Tetracycline fibers have been also used in the treatment of peri-implantitis and have showed a favorable effect on clinical and microbiological parameters (Renvert et al 2008). Minocycline microspheres and local application of doxycycline have been used in the therapy of peri-implantitis as well (Renvert et al 2008).

In one randomized controlled clinical study the local application of minocycline microspheres as an adjunctive to supra- and submucosal scaling for the treatment of peri-implantitis showed a greater reduction in mean peri-implant pocket depths and in bleeding in deepest sites compared with chlorhexidine gel (Renvert et al 2006). However, it must be noted that lesions were restricted at the 3 first coronal threads. Metronidazole alone or in combination with amoxicillin has been shown to be effective in suppressing gram-negative anaerobic microorganisms generally associated with peri-implantitis in humans (Heitz-Mayfield and Lang 2004). Due to the variety of the peri-implantitis associated bacteria, microbial tests may be advantageous prior to antibiotic selection (Heitz-Mayfield and Lang 2004).

To date, regarding the systemic administration of antibiotics as adjunctives to mechanical therapy of

peri-implantitis, no randomized controlled clinical trial have been conducted (Renvert et al. 2008, Kotsovilis et al. 2008). In addition, studies of lower statistical value (case series) don't provide enough evidence to draw safe conclusion about the effect of antibiotics alone on the outcome of mechanical treatment of peri-implantitis (Renvert et al. 2008).

A.4. Laser therapy.

Data have showed that Er:YAG laser constitutes an efficacious modality in the treatment of peri-implantitis as evidenced by improvements in clinical parameters in short-term basis of 6 months (Kotsovilis et al 2008). Thus, the long-term treatment outcome of the laser use needs to be further investigated. In addition, it must be clarified whether laser therapy has to be combined with other therapeutic modality and how many laser sessions need to be performed in order to have a stable outcome. Finally, the efficacy in the non surgical treatment of peri-implantitis of other laser's types (ND:YAG, CO₂) needs to be tested.

B. Surgical treatment.

The ultimate goal of surgical therapy is to accomplish re-osseointegration. Re-osseointegration is defined as the formation of new bone onto previously biofilm contaminated implant surface (Renvert et al 2009). Various methods have been proposed to remove bacterial deposits and to prepare implant surface for re-osseointegration such as air powder abrasion, saline wash, citric acid application, laser therapy, peroxide treatment, ultrasonic and manual debridement and application of topical antiseptics (Claffey et al 2008).

The above mentioned methods are much more effective when a full thickness flap is elevated than with the closed non surgical approach (Claffey et al 2008). Chemical measures are less effective in deposits removal than mechanical or photodynamic measures which are implicated to damage the implant surface (Claffey et al 2008). All methods without significant differences, as showed by experimental studies, are effective in resolution of inflammation but fail in themselves to achieve re-osseointegration (Claffey et al 2008).

Histological results have demonstrated a connective tissue capsule between implant surface and the adjacent bone in most cases except at the most apical extent of the defect where a bone to implant contact was observed (Claffey et al 2008). Quite paradoxically, although smooth implant surface is easier to be decontaminated, rough implant surfaces demonstrated more

re-osseointegration than smooth implant surfaces (Renvert et al 2009). This could be attributed to the potential of rough surfaces to support the coagulum and thus facilitate greater bone healing in contact with the implant surface (Renvert et al 2009).

However, it must be noted that data regarding the efficacy of various decontamination of the implant surface methods in conjunction with flap elevation in humans are rare (Claffey et al 2008, Maximo et al 2009). In one report it was demonstrated a favorable effect of the above mentioned treatment modality on clinical and microbiological parameters (Maximo et al 2009). However, these parameters were assessed in a short-term basis (3 months) (Maximo et al 2009). In another study disease resolution was achieved at 60% of treated sites (Romeo et al 2007). However, no safe conclusion can be drawn due to systemically administration of antibiotics (Romeo et al 2007).

In an effort for even more predictable outcome of surgical therapy, guided tissue and bone regeneration have been applied. Autogenous bone, allograft, xenograft, non resorbable and resorbable membranes have been used. Results from experimental studies vary. More specifically, bone fill of peri-implant lesion varied from 19.5% (Nociti et al 2001a, Nociti et al 2001b) to 55.74% (Machado et al 1999, Machado et al 2000) and re-osseointegration from 23% (Shou et al 2003b) to 45% (Shou et al 2003c, Shou et al 2003d). In general regenerative procedures tended to result in more bone fill and re-osseointegration than debridement alone (Claffey et al 2008). Very anticipated but rare are the data regarding agents promoting regeneration (platelet enriched fibrin glue and rhBMP-2)(Claffey et al 2008).

Clinical studies provide evidence that regeneration procedures improved clinical parameters (Claffey et al 2008). However, the contribution of barrier membranes to the final treatment outcome is not yet clarified (Claffey et al 2008). Schwarz et al (2009) investigated the 4-year outcomes following surgical regenerative therapy of peri-implantitis lesions using either a nanocrystalline hydroxyapatite (NHA) or natural bone mineral on combination with collagen membrane (NBM+CM). The application of (NBM+CM) resulted in higher peri-implant pocket depth reductions (NBM+CM: 2.5±0.9 mm versus NHA: 1.1±0.3 mm) and peri-implant "attachment" level gains (NBM+CM: 2.0±1.0 mm versus NHA: 0.6±0.5 mm).

The statistic value of this study (case series) does not allow drawing general conclusions. On the contrary, Khoury and Bouchmann failed to observe differences in peri-implant pocket depth reduction between

Plaque	Bleeding on probing	Pus	Peri-implant pocket depth	Radiographically detected bone loss	Treatment*
+/-	-	-	< 4	-	(A)
+	+	-	< 4	-	A
+	+	+/-	4-5	+/-	A+B
+	+	+/-	> 5	+	A+B+C
+	+	+/-	> 5	++	A+B+C+D
+	+	+/-	> 5	+++	E

Table 2. CIST protocol (Cumulative Interceptive Supportive Therapy).

***A** = Mechanical cleansing and improvement of patient's oral hygiene. Removal of hard deposits with soft scalers, polishing with rubber cup and paste. Instructions for more effective oral hygiene practices.

B = Antiseptic therapy. Rinses with 0.1-0.2% chlorhexidine digluconate, pocket irrigations with 0.2% chlorhexidine or local applications of chlorhexidine gel.

C = Antibiotic therapy. Systemic agent selected on the basis of microbiological test or treatment with local delivery devices.

D = Surgical therapy to change tissue structure. Gingivectomy, apically repositioned flap, osteoplasty or guided bone regeneration procedure.

E = Explantation.

subjects that were treated with combination of barrier membrane-graft material and subjects that were treated with graft material alone.

Finally, Roos-Jansåker et al (2007a) found greater reduction of peri-implant pocket depth (3.4 mm) when peri-implantitis lesions were treated only with graft material comparing with peri-implantitis lesions which were treated with the combination of graft material-barrier membrane (2.9 mm).

It must be noted that both experimental and clinical studies don't provide evidence regarding the peri-implant defect configuration. Schwarz et al (2007) reported that the most common feature in both naturally occurring in humans and ligature-induced peri-implantitis lesions in animals is a combined defect configuration including a supracrestal (Class II) and an intrabony aspect (Class I). The latter could be differentiated into five categories (Ia-e) (Schwarz et al 2007). The most frequently (Ie: 55.3%) is the one exhibited a circular bone resorption under the maintenance of buccal and lingual-palatal plate. This was followed by buccal dehiscence defects revealing a semicircular bone resorption to the middle of the implant body (Ib: 15.8%), and buccal dehiscence defects with circular

bone resorption under the maintenance (Ic: 13.3%) or loss (Id: 10.2%) of the lingual plate.

The conventional buccal dehiscence defects exhibit the lowest frequency (Ia: 5.4%) (Schwarz et al. 2007). When it comes to periodontal intrabony defects, it has been documented that as many the walls of the defect are present, the more predictable the regenerative procedures (Cortellini et al. 1993a, 1993b). Similarly, Schwarz et al. (2010) using the combination of barrier membrane and xenograft to treat peri-implant defects of class Ib, Ic and Ie, observed more favorable effect on clinical parameters of class Ie defects comparing class Ib and Ic defects. Finally, the combination of surgical therapy with systemic administration of antibiotics needs to be further investigated by clinical studies (Claffey et al. 2008).

It is known from the surgical therapy of periodontitis, that when the configuration of an intrabony defect doesn't allow the application of regenerative procedure, the resective surgical pocket obliteration is recommended. Thus, an apically repositioned flap may be applied to obliterate peri-implant pockets (Claffey et al. 2008). However, resective surgeries cause an exposure of the implant surface to the oral cavity, resulting in bacteria accumulation and in ineffective hygiene. Romeo et al (2007) compared the efficacy of the resective surgery alone or in combination with modification of the implant surface (implantoplasty). A full mouth disinfection was carried out and systemic antibiotics were administered. 3 years after the application of the combined treatment (resective surgery-implantoplasty), statistically significant less peri-implant bone loss was observed (Romeo et al. 2007).

The choice of the appropriate treatment modality is determined by the signs and symptoms of the peri-implant pathology. The CIST (Cumulative Interceptive

Supportive Therapy) protocol was introduced by Lang et al. (1997) and provides treatment guidelines based on clinical (plaque, bleeding or suppuration on probing, peri-implant pocket depth) and radiographical (peri-implant bone loss) parameters (table 2). Contemporary data confirm the efficacy of treatment modalities recommended on CIST protocol (Kotsovilis et al. 2008). However, CIST protocol doesn't include laser therapy and the treatment indications when peri-implant pocket depth >5mm are relatively subjective.

TREATMENT OF RETROGRADE PERI-IMPLANTITIS

In the literature no scientific documentation but only simple references are present regarding the treatment of the retrograde peri-implantitis. Treatment is exclusively surgical, as the inflammatory lesion lies within the bone. Quirynen et al 2005 recommended a flap elevation and granulation tissue curettage. Dahlin et al (2009), however, regarded that granulation tissue is very difficult to be removed from a rough implant surface compromising the osseous regeneration. Thus, they have recommended as treatment option to remove the apical portion of the implant.

CONCLUSIONS

- Peri-implant tissue health and long-term survival of both implants and implant supported restorations should not be taken as granted.
- Bacteria in conjunction with risk factors acting synergically, induce primarily inflammation and secondly destruction of the peri-implant tissues.
- Implant patients should follow a strict maintenance program. During this period a meticulous oral hygiene and regular follow up of peri-implant and periodontal tissues is performed. Each session is comprised of motivation and reinstruction regarding oral hygiene, clinical and when necessary radiographical examination. These procedures provide data to assess the status of the peri-implant tissues.
- The ultimate goal is the prevention and the early diagnosis of peri-implantitis, as current treatment modalities neither lead to predictable outcomes nor to complete resolution of the disease, particular when it comes to advanced peri-implant destruction.
- Finally, in daily clinical practice dental implants should never be regarded as the primary solution on every dental problem, but as an alternative. Dental implants should never substitute the value of conventional dentistry (endontology, periodontology, dental surgery etc) on survival of natural teeth.

REFERENCES

- Albrektsson T, Isidor F: Consensus report of Session IV. In Lang N P, Karring T. Proceedings of the 1st European Workshop on Periodontology, Quintessence Publishing Co, London, 1994:365-369.
- Aloufi F, Bissada N, Ficara A, Faddoul F, Al-Zahrani M S: Clinical Assessment of Peri-implant Tissues in Patients with Varying Severity of Chronic Periodontitis. *Clinical Implant Dentistry and Related Research* 2009; 11:37-40.
- Astrand P, Engquist B, Anzen B, Bergendal T, Hallman M, Karlsson U, Kvit S, Lysell L, Rundcranz T: A three-year follow up report of a comparative study of ITI Dental Implants and Brånemark System implants in the treatment of the partially edentulous maxilla. *Clinical Implant Dentistry and Related Research* 2004; 6:130-141.
- Behneke A, Behneke N: Επανάλεγχος και φροντίδα. Koeck B, Wagner W. Εμφυτευματολογία. Laterre, Αθήνα, 2004: 317-349.
- Berglundh T, Gislason O, Lekholm U, Senerby L, Lindhe J: Histopathological observations on human peri-implantitis lesions. *Journal of Clinical Periodontology* 2004; 31:341-347.
- Berglundh T, Persson L, Klinge B: A systematic review of the incidence of biological and technical complications in implant dentistry reported in prospective longitudinal studies of at least 5 years. *Journal of Clinical Periodontology* 2002; 29(Suppl. 3):197-212.
- Brägger U, Hugel-Pisoni C, Bürgin W, Buser D, Lang N P: Correlations between radiographic, clinical and mobility parameters after loading of oral implants with fixed partial dentures. A two-year longitudinal study. *Clinical Oral Implants Research* 1996; 7:230-239.
- Claffey N, Clarke E, Polyzois I, Renvert S: Surgical treatment of peri-implantitis. *Journal of Clinical Periodontology* 2008; 35(Suppl. 8):316-332.
- Cortellini P, Pini-Prato G, Tonetti M S: Periodontal regeneration of human intrabony defects. I. Clinical measures. *Journal of Periodontology* 1993a; 64:254-259.
- Cortellini P, Pini-Prato G, Tonetti M S: Periodontal regeneration of human intrabony defects. II. Re-entry procedures and bone measures. *Journal of Periodontology* 1993b; 64:261-268.
- Dahlin C, Nikfarid H, Alsen B, Kashani H: Apical Peri-implantitis: Possible Predisposing Factors, Case reports, and Surgical Treatment Suggestions. *Clinical Implant Dentistry and Related Research* 2009; 11:222-227.
- Duyck J, Naert I: Failure of oral implants: aetiology, symptoms and influencing factors. *Clinical Oral Investigation* 1998; 2:102-114.
- Ericsson I, Persson L G, Berglundh T, Edlund T, Lidhe J: The effect of antimicrobial therapy on peri-implantitis lesions. An experimental study in the dog. *Clinical Oral Implants Research* 1996; 7:320-328.
- Etter T H, Hakanson I, Lang N P, Trejo P, Caffesse R G: Healing after standardized clinical probing of the peri-implant soft tissue seal: a histomorphometric study in

- dogs. *Clinical Oral Implants Research* 2002; 13:571-580.
- Felo A, Shilby O, Ciancio S G, Lauciello F R, Ho A: Effects of subgingival chlorhexidine irrigation on peri-implant maintenance. *American Journal of Dentistry* 1997; 10:107-110.
- Feloutzis A, Lang N P, Tonetti M S, Bürgin W, Brägger U, Buser D, Duff G W, Kornmann K S: IL-1 gene polymorphism and smoking as risk factors for peri-implant bone loss in a well-maintained population. *Clinical Oral Implants Research* 2003; 14:10-17.
- Ferreira S D, Silva G L, Cortelli J R, Costa J E, Costa F O: Prevalence and risk variables for peri-implant disease in Brazilian subjects. *Journal of Clinical Periodontology* 2006; 33:929-935.
- Fourmoussis I, Brägger U: Radiologic interpretation of peri-implant structures. In: Lang N P, Karring T, Lindhe J. *Proceedings of the 3rd European Workshop on Periodontology Implant Dentistry*, Quintessence Publishing Co, Berlin 1999: 228-241.
- Fransson C, Wennström J, Tomasi C, Berglundh T: Extent of peri-implantitis-associated bone loss. *Journal of Clinical Periodontology* 2009; 36:357-363.
- Φουρμούζης Ι. Περιεμφτευματίτιδα. Στο: Αλεξανδρίδης Κ Α. *Εισαγωγή στην Εμφτευματολογία. Ιατρικές εκδόσεις Λίτσας, Αθήνα, 2003:161-174.*
- Galindo-Moreno P, Fauri M, Avila-Ortiz G, Fernandez-Barbero J E, Cabrera-Leon A, Sanchez-Fernandez E: Influence of alcohol and tobacco habits on peri-implant marginal bone loss: A prospective study. *Clinical Oral Implant Research* 2005; 16:579-586.
- Gröndahl H G: Radiographic examination. In: Lindhe J, Karring T, Lang N P. *Clinical Periodontology and implant dentistry*. Blackwell Munksgaard Publishing Co, Copenhagen, Denmark, 2003: 838-851.
- Gualini F, Berglundh T: Immunohistochemical characteristics of inflammatory lesions at implants. *Journal of Clinical Periodontology* 2003; 30:14-18.
- Heitz-Mayfield L J A, Lang N P: Antimicrobial treatment of peri-implant diseases. *International Journal of Oral and Maxillofacial Implants* 2004; 19(Suppl.):128-139.
- Heitz-Mayfield L J A: Peri-implant diseases: diagnosis and risk indicators. *Journal of Clinical Periodontology* 2008; 35(Suppl. 8):292-304.
- Karoussis I, Brägger U, Salvi G E, Bürgin W, Lang N P: Effect of the implant design on survival and success rates of titanium oral implants: a 10-year prospective cohort study of the ITI Dental Implant System. *Clinical Oral Implants Research* 2004a; 15:8-17.
- Karoussis I, Kostovilis S, Fourmoussis I: A comprehensive and critical review of dental implant prognosis in periodontally compromised partially edentulous patients. *Clinical Oral Implant Research* 2007; 18:669-679.
- Karring E S, Stavropoulos A, Elegaard B, Karring T: Treatment of peri-implantitis by the Vector system. A pilot study. *Clinical Oral Implants Research* 2005; 16:362-369.
- Khoury F, Buchmann R: Surgical therapy of peri-implant disease: a 3-year follow-up study of cases treated with 3 different techniques of bone regeneration. *Journal of Periodontology* 2001; 72:1498-1508.
- Kotsovilis S, Karoussis I K, Trianti M, Fourmoussis I: Therapy of peri-implantitis: a systematic review. *Journal of Clinical Periodontology* 2008; 35:621-629.
- Καρούσης Ι, Κωτσοβίλης Σ, Φελουτζής Α, Φουρμούζης Ι: Διάγνωση και αντιμετώπιση της περιεμφτευματίτιδας. *Οδοντοστοματολογική Πρόοδος* 2009; 63:168-195.
- Lachmann S, Kimmerla-Muller E, Axmann D, Scheideler L, Weber H, Haas R: Associations between peri-implant crevicular fluid volume, concentrations of crevicular inflammatory mediators, and composite IL-1A-889 and IL-1B +3954 genotype. A cross-sectional study on implant recall patients with and without clinical signs of peri-implantitis. *Clinical Oral Implants Research* 2007; 18:212-223.
- Laine M, Leonhardt A, Roos-Jansaker A, Pena A S, van Winkelhoff A J, Winkel E G, Renvert S: IL-1RN gene polymorphism is associated with peri-implantitis. *Clinical Oral Implants Research* 2006; 17:380-385.
- Lang N P, Mombelli A, Tonetti M S, Brägger U, Hämmerle C H F: Clinical trials on therapies for peri-implant infections. *Annual Periodontology* 1997; 2:343-356.
- Lang N P, Wetzel A C, Stich H, Caffesse R G: Histologic probe penetration in healthy and inflamed peri-implant tissues. *Clinical Oral Implants Research* 1994; 5:191-201.
- Lindhe J, Berglundh T, Ericsson I, Liljenberg B, Marinello C: Experimental breakdown of peri-implant and periodontal tissues. A study in the beagle dog. *Clinical Oral Implants Research* 1992; 3:9-16.
- Luterbacher S, Mayfield L, Brägger U, Lang N P: Diagnostic characteristics of clinical and microbiological tests for monitoring periodontal and peri-implant mucosal tissue conditions during supportive periodontal therapy (SPT). *Clinical Oral Implants Research* 2000; 11:521-529.
- Machado M A N, Stefani C M, Sallum E A, Sallum E W, Tramontina V A, Nociti F H Jr: Treatment of ligature-induced peri-implantitis defects by regenerative procedures: a clinical study in dogs. *Journal of Oral Science* 1999; 41:181-185.
- Machado M A N, Stefani C M, Sallum E A, Sallum E W, Tramontina V A, Nogueira-Fihlo G R, Nociti F H Jr: Treatment of ligature-induced peri-implantitis defects by regenerative procedures. Part II: a histometric study in dogs. *Journal of Oral Science* 2000; 42:163-168.
- Marinello C, Berglundh T, Ericsson I, Klinge B, Glantz P O, Lindhe J: Resolution of ligature induced peri-implantitis lesions. An experimental study in the dog. *Clinical Oral Implants Research* 1995; 22:475-479.
- Mau J: On statistics of success and loss for dental implants. *International Dental Journal* 1993; 43:254-261.
- Maximo M B, de Mendonca A C, Santos V R, Figueiredo L C, Feres M, Duarte P M: Short-term clinical and microbiological evaluations of peri-implant diseases before

- and after mechanical anti-infective therapies. *Clinical Oral Implants Research* 2009; 20:99-108.
- McAllister B S, Masters D, Meffert R M: Treatment of implants demonstrating periapical radiolucencies. *Pract Proced Aesthet Dent* 1992; 4:37-41.
- Mombelli A, Lang N P: The diagnosis and treatment of peri-implantitis. *Periodontology* 2000 1998; 17:63-76.
- Mombelli A, Muhle T, Brägger U, Lang N P, Bürgin W B: Comparison of periodontal and peri-implant probing by depth-force pattern analysis. *Clinical Oral Implants Research* 1997; 8:448-454.
- Mombelli A, Van Osten M A, Schürch E, Lang N P: The microbiota associated with successful or failing osseointegrated titanium implants. *Oral Microbiology and Immunology* 1987; 2:145-151.
- Nociti F H Jr, Machado M, Stefani C M, Sallum E A, Sallum A W: Absorbable versus non absorbable membranes and bone grafts in the treatment of ligature-induced peri-implantitis defects in dogs. Part I. A clinical investigation. *Clinical Oral Implants Research* 2001b; 12:115-120.
- Nociti F H Jr, Machado M, Stefani C M, Sallum E A: Absorbable versus non absorbable membranes and bone grafts in the treatment of ligature-induced peri-implantitis defects in dogs: a histometric investigation. *International Journal of Oral and Maxillofacial Implants* 2001a; 16:646-652.
- Pjetursson B E, Tan K, Lang N P, Brägger U, Egger M, Zwahlen M: A systematic review of the survival and complications rates of fixed partial dentures (FPD's) after an observation period of at least 5 years. I. Implant supported FPD's. *Clinical Oral Implants Research* 2004; 15:625-642.
- Porras R, Anderson G B, Caffesse R, Narendran S, Trejo P M: Clinical response to 2 different therapeutic regimens to treat peri-implant mucositis. *Journal of Periodontology* 2002; 73:1118-1125.
- Quirynen M, Vogels R, Alsaadi G, Naert I, Jacobs R, van Steenberghe D: Predisposing conditions for retrograde peri-implantitis, and treatment suggestion. *Clinical Oral Implants Research* 2005; 16:599-608.
- Reiser G M, Nevins M: The implant periapical lesion. Aetiology, prevention, and treatment. *Comped Contin Educ Dent* 1995; 16:768-772.
- Renvert S, Lessem J, Danlen G, Lindahl C, Svensson M: Topical minocycline microspheres versus topical chlorhexidine gel as an adjunct to mechanical debridement of incipient peri-implant infections. A randomized clinical trial. *Journal of Clinical Periodontology* 2006; 33:362-369.
- Renvert S, Polyzois I, Maguire R: Re-osseointegration on previously contaminated surfaces: a systematic review. *Clinical Oral Implants Research* 2009; 20 (Suppl. 4):216-227.
- Renvert S, Roos-Jansåker A M, Claffey N: Non surgical treatment of peri-implant mucositis and peri-implantitis: a literature review. *Journal of Clinical Periodontology* 2008; 35(Suppl. 8):305-315.
- Romeo E, Lops d, Chiapasco M, Ghisolfi M, Vogel G: Therapy of peri-implantitis with respective surgery. A 3-year clinical trial on rough screw-shaped oral implants. Part II: radiographic outcome. *Clinical Oral Implants Research* 2007; 18:179-187.
- Roos-Jansåker A M, Renvert H, Lindahl C, Renvert S: Nine to fourteen-year follow up of implant treatment. Part III: factors associated with peri-implant lesions. *Journal of Clinical Periodontology* 2006b; 33:296-301.
- Roos-Jansåker A M, Renvert H, Lindahl C, Renvert S: Surgical treatment of peri-implantitis using a bone substitute with or without a resorbable membrane: a prospective cohort study. *Journal of Clinical Periodontology* 2007a; 34:625-632.
- Salvi G E, Bardet P, Lang N P: Clinical parameters in longitudinal implant studies, Consensus report of Session C. In Lang N P, Karring T, Lindhe J. *Proceedings of the 3rd European Workshop on Periodontology. Implant Dentistry*, Quintessence Publishing Co, Berlin 1999: 217-227.
- Schwarz F, Bieling K, Bonsmann M, Latz T, Becker J: Non-surgical treatment of moderate and advanced peri-implantitis lesions: a controlled clinical study. *Clinical Oral Investigation* 2006a; 10:279-288.
- Schwarz F, Hertel M, Sager M, Bieling K, Sculean A, Becker J: Comparison of naturally occurring and ligature-induced peri-implantitis bone defects in humans and dogs. *Clinical Oral Implants Research* 2007; 18:161-170.
- Schwarz F, Sahm N, Bieling K, Becker J: Surgical regenerative treatment of peri-implantitis lesions using a nanocrystalline hydroxyapatite or a natural bone mineral in combination with a collagen membrane: a four-year clinical follow-up report. *Journal of Clinical Periodontology* 2009; 36:807-814.
- Schwarz F, Sahm N, Schwarz K, Becker J: Impact of defect configuration on the clinical outcome following surgical regenerative therapy of peri-implantitis. *Journal of Clinical Periodontology* 2010; 37:449-455.
- Schwarz F, Sculean A, Rothamel D, Schwenzer K, Georg T, Becker J: Clinical evaluation of an ER: YAG laser for nonsurgical treatment of periimplantitis: a pilot study. *Clinical Oral Implant Research* 2005; 16:44-52.
- Shou S, Holmstrup P, Jorgensen T, Skovgaard L T, Stoltze K, Hjorting-Hansen E, Wenzel A: Anorganic porous bovine-derived bone mineral (Bio-Oss) and ePTFE membrane in the treatment of peri-implantitis in cynomolgus monkeys. *Clinical Oral Implants Research* 2003b; 14:535-547.
- Shou S, Holmstrup P, Jorgensen T, Stoltze K, Hjorting-Hansen E, Wenzel A: Autogenous bone graft and ePTFE membrane in the treatment of peri-implantitis. I. Clinical and radiographic observations in cynomolgus monkeys. *Clinical Oral Implants Research* 2003c; 14:391-403.
- Shou S, Holmstrup P, Skovgaard L T, Stoltze K, Hjorting-Hansen E, Gundersen H J G: Autogenous bone graft and ePTFE membrane in the treatment of peri-implantitis. II. Stereologic and histologic observations in cy-

- nomolgus monkeys. *Clinical Oral Implants Research* 2003d; 14:404-411.
- Shou S, Holmstrup P, Stoltze K, Hjorting-Hansen E, Fiehn N E, Skovgaard L T: Probing around implants and teeth with healthy or inflamed peri-implant mucosa-gingiva. A histologic comparison in cynomolgus monkeys (*Macaca fascicularis*). *Clinical Oral Implants Research* 2002; 13:113-126.
- Strietzel F P, Reichart P A, Kale A, Kulkarni M, Wegner B, Kuchler I: Smoking interferes with the prognosis of dental implant treatment: a systematic review and meta-analysis. *Journal of Clinical Periodontology* 2007; 34:523-544.
- Strooker H, Rohn S, Winkelhoff A J: Clinical and microbiological effects of chemical versus mechanical cleansing in professional supportive implant therapy. *International Journal of Oral and Maxillofacial Implants* 1998; 13:845-850.
- Tabanella G, Nowzari H, Slots J: Clinical and Microbiological Determinants of Ailing Dental Implants. *Clinical Implant Dentistry and Related Research* 2009; 11:24-36.
- Van Winkelhoff A J, Goene R J, Benschop C, Folmer T: Early colonization of dental implants by putative periodontal pathogens in partially edentulous patients. *Clinical Oral Implants Research* 2000; 11:511-520.
- Wennström J L, Ekenstubbé A, Gröndahl K, Karlsson S, Lindhe J: Oral rehabilitation with implant-supported fixed partial dentures in periodontitis-susceptible subjects. A 5-year prospective study. *Journal of Clinical Periodontology* 2004; 31:713-724.
- Wennström J, Palmer R: Consensus report of Session C: Clinical trials. In: Lang N P, Karring T, Lindhe J. *Proceedings of the 3rd European Workshop on Periodontology. Implant Dentistry*, Quintessence Publishing Co, Berlin 1999: 255-259.
- Zitzmann N U, Berglundh T, Marinello C P, Lindhe J: Experimental peri-implant mucositis in man. *Journal of Clinical Periodontology* 2001; 28:517-523.
- Zitzmann N U, Berglundh T: Definition and prevalence of peri-implant diseases. *Journal of Clinical Periodontology* 2008; 35 (Suppl. 8):286-291.

Orthodontic Mini-Implants: Answers to common questions.

Konstantina Syrrakou¹, Demetrios Halazonetis²

SUMMARY

Orthodontic mini-implants (OMI) are contemporary means of anchorage that are increasingly preferred over traditional anchorage techniques during orthodontic treatment. The aim of this literature review was to address the most common questions regarding OMI use in orthodontic practice.

OMIs offer a wider choice of insertion sites than conventional prosthetic implants, due to their smaller size. Insertion is feasible even in tight spaces, between roots of teeth, but certain anatomical structures, such as the sinus, should be avoided. Various lengths, diameters and shapes are available to facilitate treatment planning. Factors such as bone quality, available space between the roots of teeth, the condition of the soft tissues, the age and oral hygiene of the patient, including habits (e.g. smoking), should be considered in order to decide on the appropriate implant location. Such factors will also dictate the inclination of the implant relative to the alveolar surface, the exposure of the implant's head in the oral cavity, and surgical details, such as the necessity of a gingival incision during placement.

Failure of OMIs is associated with increased mobility and eventual loss. Failure factors include iatrogenic causes, complications arising from the patient's dental and medical history, and clinical characteristics of the implants. The use of OMIs has expanded the possibilities of contemporary orthodontic treatment. However, further research is required, for OMIs to become firmly established in everyday orthodontic practice (*Eur J Dent Sc* 2012; 1:5-14).

►**Key-Words:** orthodontic mini-implants, temporary anchorage devices, orthodontic anchorage, orthodontic treatment.

INTRODUCTION

One of the great challenges faced by the clinician in contemporary orthodontics, is anchorage control. Anchorage is governed by Newton's third law, which states that for every force applied on an object there is a counteraction force; equal in magnitude but opposite in direction. In orthodontics, a force applied on a tooth will generate another force, applied on the

anchor tooth or device, which will be, equal but opposite. Therefore, in order to achieve controlled tooth movement without unwanted side effects it is necessary to obtain adequate anchorage control (McGuire et al., 2006). The term 'anchorage' may refer to the actual object providing support (usually a tooth or group of teeth), or to the capability of a tooth or a device to prevent the occurrence of undesirable tooth movement (Skeggs et al., 2007).

Orthodontists have been using many intraoral and extraoral devices to achieve tooth movement with minimum anchorage loss. Extraoral devices usually require good patient cooperation. Problems arising during treatment due to lack of patient's cooperation may interfere with treatment outcome. In addition, these extraoral devices are connected via

¹Dental surgeon in private practice, Athens, Greece

²Associate professor, Department of Orthodontics, University of Athens, Athens, Greece

Correspondence to: Demetrios Halazonites, University of Athens Dental School, Thivon 2, Goudi, Athens, 115 27 Greece.

email: dhal@dhal.com

Submitted, January 2012; revised and accepted, April 2012.

bands or brackets to teeth in order to apply forces. When teeth are missing, proper anchorage may be difficult, if not impossible (Odman et al., 1994). That is why extraoral devices are preferably used on children, teenagers and adults who do have the necessary anchor teeth.

Conventional intraoral devices are frequently more demanding and complicate the treatment plan. Many alternative intraoral means of anchorage such as implants, onplants, orthodontic mini-implants (Kanomi, 1997; Costa et al., 1998; Papadopoulos, Tarawneh, 2007; Kyung et al., 2003) have been used to reduce the need of patient cooperation (Park et al., 2006).

WHAT ARE ORTHODONTIC MINI-IMPLANTS?

According to the British Orthodontic Society "Orthodontic Mini-Implants" (O.M.I.) are described as "Small screws placed temporarily in the jaw to provide anchorage for forces to move the teeth" (Glossary of Orthodontic Terms. <http://www.bos.org.uk/orthodonticsandyou/Information+for+Patients/glossary>, Accessed on 7/12/2011). They belong, along with onplants and miniplates, in the group of Temporary Anchorage Devices or TADs (McGuire et al., 2006).

In the literature, one can identify two terms: "miniscrews/mini-implants" and "microscrews/micro-implants" (McGuire et al., 2006). The basic difference between them, according to Berens et al. (2006), lies in their external diameter. A miniscrew has an external diameter of 2 mm or more, whereas a micro-screw is up to 1.9 mm (Berens et al., 2006). This difference, however, has not been internationally approved so technically every term used (microscrew, miniscrew, micro-implant, mini-implant, onplant, miniplate, TAD) refers to the same object. Choo and colleagues insist there is a need in the orthodontic society for a qualified committee to end the confusion and properly define the term (Choo et al., 2009).

It is really interesting to follow the path of the TADs to their present form and use. Skeletal anchorage began in 1945, when Gainsforth and Higley first used vitallium screws on a dog (Gainsforth, Higley, 1945). Failures that occurred between 16-31 days, paused orthodontic implants' research for a period of time, although vitallium and other material implants were used for prosthetic reasons.

Almost thirty years later, Brånemark and his colleagues (1977) reported the first successful implant osseointegration and research turned towards skeletal anchorage once more. Creekmore and Eklund

(1983) first reported the use of miniscrews similar to the ones used in oral surgeries treating jaw fractures. Later on, many researchers presented the use of orthodontic implants as anchorage during the orthodontic treatment (Roberts et al., 1984; Turley et al., 1988; Shapiro, Kokich, 1988). Wehbrein et al (1997) also presented mini-implants as anchorage devices on dogs while Kanomi, the same year (1997) uniquely described the use of a TAD during the orthodontic treatment of a male adult patient.

HOW IMPORTANT IS THE MINISCREW'S MATERIAL AND DIMENSION

Every object implanted in the human organism should fulfill certain criteria regarding their material. The orthodontic mini-implant is placed on the mandible and maxilla, so it should be both biocompatible and non-toxic (Huang et al., 2005).

Pure titanium (P Ti) doesn't cause allergic reactions and is not carcinogen. Nevertheless, it is not frequently used for the manufacture of orthodontic mini-implants because of its low fatigue strength (Huang et al., 2005; Morais et al., 2007).

Alternatively, titanium-alloys have been widely used, such as Ti6Al14V (Eliades et al., 2009). Titanium-alloys have a high fatigue strength but their resistance to corrosion decreases and metal ionic release occurs (mostly Vanadium). To evaluate the impact of the released ions, their interaction with the organism, their quantity and their toxicity should be taken into account (Hanawa T, 2004). Orthodontic mini-implants are used for a small period of time and the forces applied are less than the ones applied on the titanium prostheses used in Orthopedics, therefore the ionic release doesn't reach toxicity levels and their use is considered to be safe (Gioka et al., 2004; Morais et al., 2007). Okazaki et al, in 2004, demonstrated in a research on rats that the quantity of the released titanium ions increases the more they are in use. This phenomenon is mostly observed in the implants of pure titanium than in the implants of titanium alloy until the 12th week (Okazaki et al., 2004). After the 12th week, Okazaki observes that the released titanium remains the same. Ionic release has been associated to clinical implant failure, biological interaction and allergic reactions, however no important topical or systematical damages have been reported in the literature regarding the pure titanium implants (Sedarat et al., 2001).

Stainless steel is another material used for mini-implants. However, it is not as widely used as tita-

nium-alloy (McGuire et al., 2006; Papadopoulos, Tarawneh, 2007), possibly due to its lower elasticity in comparison to titanium (Pienkowski et al., 1998; Christensen et al., 2000).

Skepticism about the implant materials that have occasionally been used for the manufacture of mini-implants has led to the development of new alloys such as Ti6Al7Nb and pure titanium with nanoscale grains. They are considered to have suitable mechanical properties, to be more corrosion resistant and biocompatible to human tissues and fluids.

Successful placement and function of the orthodontic mini-implant may directly be connected to O.MI.'s size and shape. Primary stability and resistance to mechanical forces are two parameters highly affected by the length and diameter of the mini-implant (Huang et al., 2005).

Conventional orthodontic implants restricted clinicians in regard to placement sites. They could only be placed in edentulous or retromolar areas (Kanomi, 1997). Nowadays, that the orthodontic mini-implant's size is reduced by up to 50%, these placement sites have increased (Kyung et al., 2003; Deguchi et al., 2003). Furthermore, the use of a smaller screw suggests a less traumatic surgical procedure as well as a shorter healing time (Deguchi et al., 2003), parameters of high concern to both clinician and patient. In 1997, Kanomi introduced the first mini-implant whose length was 5 mm. and diameter was 1 mm. inspired by the screws used at the time in plastic surgery.

Clinical experience and research have demonstrated mini-implants, compared to the larger diameter conventional implants, can be placed in a wider range of sites (Fritz et al., 2004). The orthodontic mini-implants range from 1-2.3 mm diameter and 4-14 mm. length while there are also reports of the use of 21 mm. Diameters smaller than 1.2 mm. may lead to mini-implant's fracture (Turley et al., 1988; Okazaki et al., 2004) during the placement and removal, especially if osseointegration has been achieved (Morais et al., 2007). Clinical and radiographical examinations are necessary to choose the appropriate size determined by adjacent anatomical structures such as the sinus, the roots of the teeth, the inferior alveolar nerve, the incisal foramen, the greater palatine artery and nerve (Wilmes et al., 2008) so that these structures remain intact (Janssen et al., 2008). The mini-implant's length doesn't seem to affect its primary stability, preservation and function during the treatment (Cheng et al., 2004).

In the literature we encounter the terms "outer" and "inner" diameter. The inner diameter of the core outlines the fracture risk of the mini-implant. The outer diameter includes the inner diameter and the diameter of the helices. Depending on the available space, the mini-implant is selected according to its outer diameter. In most articles the term "diameter" implies the outer diameter of the mini-implant, so for consistency reasons the same pattern will be used in our article.

Mini-implants of larger diameter placed monocortically (buccally or palatally) offer greater anchorage than those with smaller diameter. However, mini-implants with smaller diameter and increased length that are placed bicortically offer equal or even greater anchorage compared to the mini-implants of larger diameter (Morarend et al., 2009). The suggested diameter is therefore 2 mm for placement in the mandible and 1.5 mm for placement in the maxilla (Kyung et al., 2006; Berens et al., 2006). The larger the diameter of the mini-implant, the easier the forces are distributed in wider osseous areas with less strain (Morarend et al., 2009). On the other hand, Wawrzinek et al (2008) suggested that osseous microfractures may be caused by increased mini-implant diameter, so careful diameter selection may influence the bone tissue condition.

Additionally, the shape of the mini-implant determines the bone-to-implant contact which is important for loading capacity and primary stability. Surgical trauma may be minimal and adequate primary stability can be achieved depending on the different available shapes (Huang et al., 2005; Janssen et al., 2008). Common shapes are cylindrical or conical with a smooth or machined surface. Clinical and research experience point out that the conical shapes provide better primary stability compared to cylindrical ones (Kyung et al., 2003; Wilmes et al., 2009).

The helices of the mini-implant can be symmetrical or not, but this doesn't seem to affect the primary stability (McGuire et al., 2006). Their shape may possibly be associated to the osseous microfractures that occur during the placement of the mini-implant, however there is no literature to support or discard this claim.

Research has shown that the machined surface of the implant is associated with the degree of osseointegration (Le Guéhennec et al., 2007). When osseointegration occurs, the removal of the implant is more difficult and therefore most mini-implants have a smooth, unmachined, unoxidized surface, prevent-

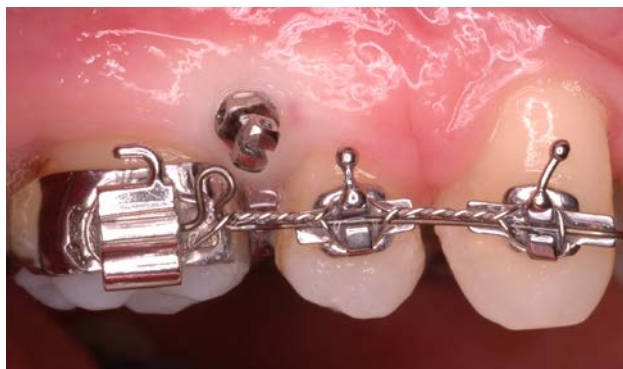

Figure 1. Bracket-like head of orthodontic mini-implant.

ing bone development and favoring soft tissue adjustment (Papadopoulos, 2008). In contrast to conventional implants, mini-implants do not fully osseointegrate but remain stable mechanically and that is why tight insertion is the key to their successful placement (Kyung et al., 2003; Janssen et al., 2008).

Orthodontic treatment plan and prevention of tissue irritation determine its head shape (figure 1). Common head shapes are spherical (single or double sphere), hexagonal and bracket-like. Some heads may also have a hole or form a hook (Papadopoulos, Tarawneh, 2007).

In conclusion, the choice of the appropriate mini-implant lies on the clinician's capability and knowledge. Factors affecting this choice that are associated with the mini-implant itself as well as the individualised treatment plan are briefly presented in Table 1. The material of choice, for the small period of time they remain intraorally, is the titanium-alloy Ti6Al4V. Although the mini-implant's length doesn't significantly affect its function, it is advised to use longer mini-implants with regards to the available space. For placement in the maxilla, the length should be at least 10 mm. and for placement in the mandible at least 8 mm. Diameter of choice should be

at least 2 mm. in the maxilla and 1.2 mm in the mandible as the purpose is to use as small a diameter as possible. The mini-implant's shape chosen is usually the conical one as the surgical trauma is consequently minimised. Furthermore, the head shape is selected regarding the forces that are to be applied and the function it should serve. With the use of bracket-like heads it is possible to achieve three dimensional tooth movement so it is the shape of choice in most treatment plans.

WHAT ARE THEIR ADVANTAGES AND THEIR CLINICAL APPLICATIONS?

In contrast to conventional implants, the O.MI's small size allows an increased number of potential insertion sites (Deguchi et al., 2003; Fritz et al., 2003) and facilitates surgical placement and removal (Yao et al., 2005; Morais et al., 2007) with less surgical trauma (Wilmes et al., 2008). The procedure can be easily performed by the orthodontist (Costa et al., 1998), so only one clinician has complete supervision and treatment control. Additionally, the patient's stress and discomfort regarding the surgery appears to be minimal (Morais et al., 2007; Fritz et al., 2004; Janssen et al. 2008). The O.MI's clinical application seems to be greatly appreciated by patients and patient instructions concerning the care of mini-implants are straightforward (Chin et al., 2007).

Furthermore, mini-implants present shorter healing time (Deguchi et al., 2003), since osseointegration is not necessary to initiate their force loading (Costa et al., 1998). Due to the immediate loading (Park et al., 2006) treatment time is significantly reduced (Morarend et al., 2009). The cost/gain analogy is also satisfactory (Fritz et al. 2004) compared to the much more expensive procedure of placing conventional implants.

Mini-implants have a wide range of clinical applications. Every orthodontic movement achieved

Material	Length	Diameter	Shape	Head shape
1- Titanium (Ti)	10 mm in the maxilla	2 mm in the maxilla	Conical Cylindrical	Bracket-like Spherical (Simple/double)
2- Ti6Al4V				
3- Ti6Al7Nb	8 mm in the mandible	1,2 mm in the mandible		Exagonal Hook With hole
4- Stainless Steel				

Table 1. Suggested technical characteristics of mini-implants.

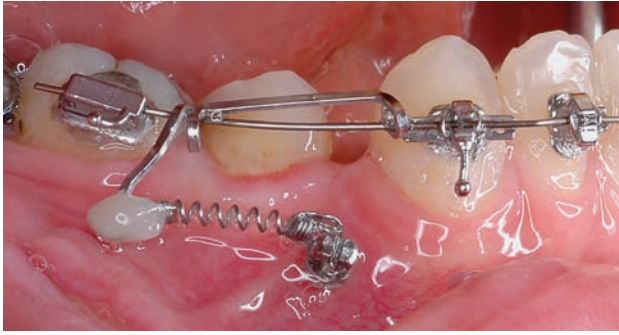

Figure 2. Congenitally missing premolar treated with mesial movement of molars and premolar for space closure. The mini-implant is used in this stage to move the front teeth mesially and buccally because they have been distally adjusted in the missing tooth space.

with conventional anchorage systems is feasible and therapeutic possibilities are increased. By combining orthodontic with prosthodontic treatment, over-erupted teeth can be intruded, otherwise the teeth would have to be endodontically treated in order to restore the occlusal level (Chang et al., 2009; McGuire et al., 2006). Researchers have also presented correction of inclined molars, semi-impacted third molars and impacted canine (Chang et al., 2009; Leung et al., 2008; Park et al., 2004). In cases of congenitally missing premolars mini-implants can be used to close the space as an alternative to prosthetic solutions (figure 2). En mass retraction is possible with no anchorage loss (Leung et al., 2008), as shown in figure 3. Teeth with extensive subgingival damage may be restored after overerupting them, whereas otherwise they would be extracted (McGuire et al., 2006). Orthodontic mini-implants seem to overcome certain side effects that occur with conventional orthodontics, such as undesirable molar buccal inclination during the use of extra-oral traction (Leung et al., 2008).

There are cases when lack of adequate space for tooth rearrangement leads to extractions. In such cases, orthodontic mini-implants allow the clinician to extract alternative teeth with doubtful long-term prognosis (endodontically treated, with large restorations or shape anomalies) instead of healthy and intact ones (McGuire et al., 2006). Several researchers have presented cases in which patients in need of ortho-surgical approach were alternatively treated with mini-implants (McGuire et al., 2006; Leung et al., 2008; Park et al., 2004; Umemori et al., 1999; Chang et al., 2004; Freudenthaler et al., 2001). When surgical correction is indicated, but the patient doesn't

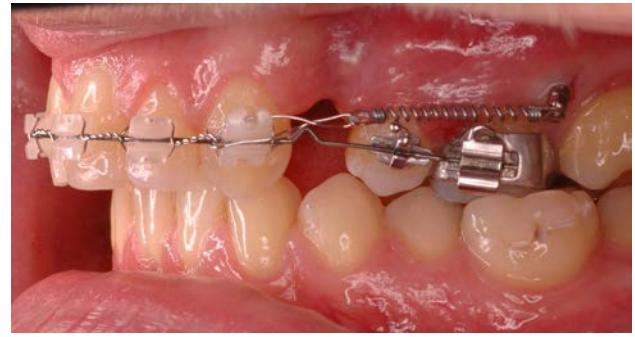


Figure 3. Retraction of incisors and canine with no anchorage loss via a spring connected to the head of the mini-implant.

wish to proceed, alternative conventional treatment plans may lead to compromised treatment result, i.e. a camouflage of the skeletal anomaly. Orthodontic mini-implants may offer, in certain cases, a result similar to ortho-surgical treatment, without the surgery (Leung et al., 2008; Polat-Ozsoy et al., 2009). More research towards this direction is necessary in order to minimise the difficult, time consuming and rather expensive surgical procedures. Further clinical and research experience may firmly place the orthodontic mini-implant in the daily practice of Orthodontics as a useful means of intraoral anchorage.

ARE THERE ANY RESTRICTIONS FROM THE PATIENT'S MEDICAL HISTORY?

The patient's health plays an important role in the successful use of the orthodontic mini-implants. Patients who suffer from systemic or metabolic diseases, bleeding disorders, patients who receive certain medication, but also those with allergies or harmful oral-associated habits, should be taken into serious consideration and their treatment plan should be individualised in accordance with their medical history.

Diabetes is a metabolic disease, characterised by decreased healing ability and immune response, vascular discrepancies, different bone metabolism and a tendency for infections (Klokkevold, Han, 2007). In such cases, the orthodontist or oral surgeon performing the placement should contact the patient's endocrinologist, so as to be fully informed about the diabetic patient's condition, and if necessary, to investigate the levels of Hemoglobin A1c (Beikler, Flemmig, 2003). The clinician should also examine the patient's immediate pre-surgery fasting blood glucose levels (the levels should be lower than 125 mg/dL to continue with surgery). When diabetes is well controlled,

topical chlorhexidine application before and after the surgery is suggested, while antibiotics (prophylactic or full treatment) can be given occasionally (Beikler, Flemmig, 2003).

Osteoporosis is a disease from which women usually suffer after entering menopause, when estrogen levels decrease and bone architecture is consequently affected, predisposing to fracture (Mellado-Valero et al., 2010). Evaluation of bone density and bone quality is considered necessary in the region where the mini-implant is to be placed (Becker et al., 2000). In cases where biphosphonates are used by the patient, contacting the patient's doctor to alter the medication or/and propose appropriate antibiotics before, during and after surgery is advised (Mellado-Valero et al., 2010).

Bleeding disorders may also necessitate an individualized treatment plan. The patient's cardiologist should change the medication (antiplatelet or anticoagulant), but in any case measures for obtaining topical haemostasis should be taken (Gupta et al., 2007). Mini-implant placement and removal may cause less tissue trauma compared to conventional implants (Okazaki et al., 2004), nevertheless, radiographic presurgical examination will prevent major vascular damage.

Gingival hyperplasia is a side effect of certain medication (such as phenytoin, niphedipine). In such cases, after careful treatment planning, appropriate mini-implant's length will be chosen so the patient can successfully perform topical oral hygiene. It is often suggested to alter patient's medication doses in accordance with the patient's neurologist's or cardiologist's opinion (Chee, Jansen, 1994; Silverstein et al., 1995; Gupta et al., 2007).

Allergic reaction occurs after contact or intake of an allergen such as latex gloves, topical anesthesia, mini-implant's material or prescribed medication i.e. analgesic/antibiotic (Ludwig, 2007). Symptoms of allergic reaction are: urticaria, oedema, rhinorhea, dyspnea, conjunctivitis, headache, abdominal cramps, thoracic oppression (Latex allergy Symptoms. <http://www.latexallergyresources.org/symptoms> Accessed on 7/12/11). In case of a known allergen it must be avoided and different treatment plan should be followed. In addition, because the allergic patient may also develop allergy to another material, the clinician should be prepared to provide first aid to a possible allergic reaction.

Smoking is a harmful habit that causes chronic lung disease, heart failure, ischemic heart disease,

lung and oral cancer and death (Ramos et al., 2010). Researchers have even associated smoking with conventional implant failure (Bain, 2000; Heitz-Mayfield, 2008). As far as mini-implants, complications in healing and vascular system caused by smoking along with non compliance to oral hygiene instructions increases local inflammation risk (Bain, 2000). Poor oral hygiene itself is directly associated to perimplantitis (Bain, 2000). Therefore, the patient should use daily a chlorhexidine solution 0,20% or a chlorhexidine gel 2% (Heitz-Mayfield, 2008) after mechanical removal of microbiotic population with a toothbrush or interproximal brush.

Furthermore, primary stability and successful use of mini-implants may also be endangered by oral habits. Continuous mechanical manipulation of the mini-implant with tongue or fingers, or even sucking movements from the buccinator muscle may affect the preservation of the mini-implant and should be avoided (Ludwig, 2007).

WHERE ARE THEY PLACED AND HOW?

Mini-implant's placement is simpler compared to conventional mini-implants and can also be performed by the orthodontist, as aforementioned (Costa et al., 1998), so only one clinician has the total supervision and control of the treatment. Selection of proper surgical procedure is guided by the desired final position of the mini-implant as well as its shape.

Conventional implants may be placed only in edentulous or retromolar areas whereas mini-implants, due to their small size can be placed in even more sites. They can be inserted in the inferior surface of the anterior nasal spine, the midpalatal suture, the infrazygomatic crest, the mandibular symphysis as well as between the roots of the teeth (Costa et al., 1998; Schnelle et al., 2004; McGuire et al., 2006).

Selection of the appropriate site and surgical approach, is a very important stage of presurgical examination. Because clinical image is not adequate, radiographs should also be taken. Radiographs provide further information concerning bone quality and quantity, adjacent anatomical structures and the appropriate dimensions and placement inclination of the mini-implant (Schnelle et al., 2004; Xun et al., 2007). Cone beam tomography gives accurate and clear images, however high levels of radiation and cost, make periapical radiographs more applicable to everyday orthodontic treatment (Kyung, et al., 2003).

There are two surgical approaches when placing a mini-implant. In one case, the orthodontic mini-

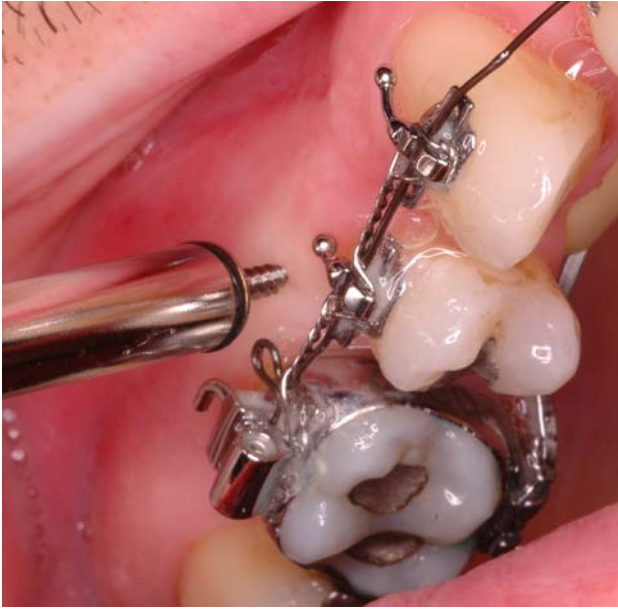

Figure 4. Mini-implant inserted manually with a screwdriver in the attached gingiva, without any flap or drilling.

implant is placed on the attached gingiva (figure 4), surgical procedure and orthodontic treatment are then simplified. After topical anesthesia the mini-implant is inserted manually with a screwdriver. In the other case, the mini-implant is inserted under movable mucosa, therefore, after the topical anesthesia, an incision is made, with or without a flap. The mini-implant is inserted as in the first case but the difference is that a ligature wire hook is attached to its head. This ligature extends in the oral cavity after the mucosa is sutured (Kyung, 2006). Force application can be immediate (Park et al., 2006), on the head of the mini-implant or on the ligature.

Complications arise when the head is under the movable mucosa, as proper oral hygiene is more difficult to perform. This has a high failure risk and that is why it is advised to use a headless mini-implant with an emerging ligature wire hook (Kyung et al., 2003). In all cases, after primary stability is achieved, oral hygiene instructions are given and chlorhexidine 0,20% solutions, analgesics (such as ibuprofen) and occasionally antibiotics (according to the patient's medical history) are suggested (McGuire, et al., 2006). Should primary stability not occur, the mini-implant is immediately removed and re-inserted in the nearest possible site or another mini-implant of a larger diameter is inserted (Kyung, et al., 2003).

The shape of the mini-implant may also affect the surgical approach. When using the cylindrical mini-

implants, it is important to drill before insertion with a low-speed contra-angle and a burr a little narrower than the mini-implant in its full length regardless of the necessity of incision. This part is omitted when using conical mini-implants. However, in cases when the underlying bone is dense, in order to facilitate insertion, a round burr can be used to make an initial drill (Chen, 2006). In all cases, it is safer to insert the mini-implant manually than with an engine-driven screwdriver in a low-speed contra-angle, because only manually may the clinician be aware of potential resistance posed by the roots of the teeth and change the mini-implant's direction or make appropriate alterations (Kyung et al., 2003).

Removing the mini-implant, after it has served its purpose, is an easy procedure. When the mini-implant is in attached gingiva, anesthesia is not necessary. The unscrewing is performed with the same screwdriver used in placement, there is no need for sutures and the healing is excellent after a few days (Fritz, 2003). When the mini-implant is under movable mucosa, after topical anesthesia, incision is made, its head is exposed, it is unscrewed and the mucosa is finally sutured.

ARE THERE ANY COMPLICATIONS?

Literature presents high success rates of mini-implants from 85-95% (Tseng et al., 2006), both in regards to their longevity and their use. Nevertheless, a 5-15% of the cases may present some complications. These complications are associated with three important factors i.e. the clinician, the patient and the mini-implant itself (Kyung et al., 2003). Therefore, it is important for both clinician and patient to be fully aware of the possible complications so as to deal with them timely and effectively.

Iatrogenic complications may be damage to anatomical structures (such as the sinus, adjacent root), mini-implant's fracture, tissue necrosis due to increased heat caused by drilling, inadequate primary mechanical stability and mini-implant's infection (Melsen, 2005). These complications can be avoided provided that the clinician conducts a thorough presurgical clinical and radiographical examination. The clinician should also be adequately trained to perform such a surgical procedure. Sufficient water irrigation for site lubrication throughout the drilling and screwing is important for avoiding tissue necrosis (Park et al., 2006). Perimplantitis is caused by the patient's negligence of oral hygiene instructions, although it is the clinician's responsibility to demon-

strate and adjust these instructions according to the patient's needs and capabilities.

The patient's medical history, age, physical condition, systematic diseases, bone and saliva quality/quantity and mucosal thickness may also lead to complications unless the clinician takes it into account (Janssen, 2008). The clinician's knowledge and preparation may reduce these complications.

Furthermore, the mini-implant's material, size, shape and surface treatment may also lead to complications and failure (Kim et al., 2005). Titanium-alloy mini-implants are preferred for their fracture and corrosion resistance, with a diameter no less than 2 mm in the maxilla and 1.2 mm in the mandible as well as a non machined/oxidised surface to avoid fractures during insertion/removal (Berens et al., 2006).

CONCLUSIONS

There is no doubt that the profile of contemporary dentists has changed in the last decades with the introduction of implants in the daily practice. Knowledge regarding prosthetic implants and implants used for orthodontic purposes is being enriched thanks to continuous scientific research.

The orthodontists' interest for skeletal anchorage is growing. Researchers worldwide present a large number of patients orthodontically treated with mini-implants and demonstrate that careful treatment design may lead to success. Orthodontic mini-implants are well documented to provide adequate skeletal anchorage and apparently with them lies the future of orthodontic treatment.

However, conventional anchorage methods are not about to be replaced by the orthodontic mini-implants, as these methods serve reliably and predictably the scientific and clinical orthodontic thought and practice. So far, mini-implants are only being used to expand treatment approach and that is why further research is required for mini-implants to be firmly accepted in everyday orthodontic practice.

REFERENCES

- Bain CA 2003 Implant installation in the smoking patient. *Periodontology* 2000 33: 185-193
- Becker W, Hujoel PP, Becker BE, Willingham H 2000 Osteoporosis and Implant Failure: An exploratory Case-Control Study. *Journal of Periodontology* 71: 625-631
- Beikler T, Flemmig TF 2003 Implants in the medically compromised patient. *Critical Review of Oral Biology and Medicine* 14: 305-16
- Berens A, Wiechmann D, Dempf R 2006 Mini- and micro-screws for temporary skeletal anchorage in orthodontic therapy. *Journal of Orofacial Orthopedics* 67: 450-8.
- Brånemark PI, Hansson BO, Adell R, Breine U, Lindström J, Hallén O, Ohman A 1977 Osseointegrated implants in the treatment of the edentulous jaw. Experience from a 10-year period. *Scandinavian Journal of Plastic and Reconstructive Surgery Suppl.* 16: 1-132
- Chang YJ, Lee HS, Chun YS 2004 Microscrew anchorage for molar intrusion. *Journal of Clinical Orthodontics* 38: 325-30.
- Chang CS, Lee Tm, Chang CH, Liu JK 2009 The effect of microrough surface treatment on miniscrews used as orthodontic anchors. *Clinical Oral Implants Research* 20: 1178-84.
- Choo H, Kim SH, Huang JC 2009 TAD, a misnomer?. *American Journal of Orthodontics and Dentofacial Orthopedics* 136: 145-6.
- Chee WW, Jansen CE 1994 Phenytoin hyperplasia occurring in relation to titanium implants: a clinical report. *International Journal of Oral and Maxillofacial Implants* 9: 107-9.
- Chen CH, Chang CS, Hsieh CH, Tseng YC, Shen YS, Huang IY, Yang CF, Chen CM 2006 The Use of Micro-implants in Orthodontic Anchorage. *Journal of Oral and Maxillofacial Surgery* 64: 1209-13.
- Cheng SJ, Tseng IY, Lee JJ, Kok SH 2004 A prospective study of the risk factors associated with failure of mini-implants used for orthodontic anchorage. *International Journal of Oral and Maxillofacial Implants* 19: 100-6
- Chin MY, Sandham A, de Vries J, van der Mei HC, Busscher HJ 2007 Biofilm formation on surface characterized micro-implants for skeletal anchorage in orthodontics. *Biomaterials* 28: 2032-40.
- Christensen FB, Dalstra M, Sejling F, Overgaard S, Bünger C 2000 Titanium-alloy enhances bone-pedicle screw fixation: mechanical and histomorphometrical results of titanium-alloy versus stainless steel. *European Spine Journal* 9: 97-103.
- Costa A, Raffaini M, Melsen B 1998 Miniscrews as orthodontic anchorage: a preliminary report. *International Journal of Adult Orthodontics and Orthognathic Surgery* 13: 201-9.
- Creekmore TD, Eklund MK 1983 The possibility of skeletal anchorage. *Journal of Clinical Orthodontics* 17:266-9.
- Deguchi T, Takano-Yamamoto T, Kanomi R, Hartsfield Jr JK, Roberts WE, Garetto LP 2003 The Use of Small Titanium Screws for Orthodontic Anchorage. *Journal of Dental Research* 82: 377-381.
- Eliades T, Zinelis S, Papadopoulos MA, Eliades G 2009 Characterization of retrieved orthodontic miniscrew implants. *American Journal of Orthodontics and Dentofacial Orthopedics* 135: 10.e1-10.e7.
- Freudenthaler JW, Haas R, Bantleon HP 2001 Bicortical titanium screws for critical orthodontic anchorage in the mandible: a preliminary report on clinical applications. *Clinical Oral Implants Research* 12: 358-63.

- Fritz U, Diedrich P, Kinzinger G, Al-Said M 2003 The anchorage quality of mini-implants towards translatory and extrusive forces. *Journal of Orofacial Orthopedics* 64: 293-304.
- Fritz U, Ehmer A, Diedrich P 2004 Clinical suitability of titanium microscrews for orthodontic anchorage-preliminary experiences. *Journal of Orofacial Orthopedics* 65: 410-8.
- Gainsfoth BL, Higley LB 1945 A study of orthodontic anchorage possibility in basal bone. *American Journal of Orthodontics and Oral Surgery* 31: 406-417.
- Gioka C, Bourauel C, Zinelis S, Eliades T, Silikas N, Eliades G 2004 Titanium orthodontic brackets: structure, composition, hardness and ionic release. *Dental Materials* 20: 693-700.
- Gupta A, Epstein JB, Cabay RJ 2007 Bleeding disorders of importance in dental care and related patient management. *Journal of Canadian Dentists Association* 73: 77-83.
- Hanawa T 2004 Metal ion release from metal implants. *Materials Science and Engineering: C* 24: 745-752
- Heitz-Mayfield LJ 2008 Peri-implant diseases: diagnosis and risk indicators. *Journal of Clinical Periodontology* 35: 292-304.
- Huang LH, Shotwell JL, Wang HL 2005 Dental implants for orthodontic anchorage. *American Journal of Orthodontics and Dentofacial Orthopedics* 127: 713-22.
- Janssen KI, Raghoobar GM, Vissink A, Sandham A 2008 Skeletal anchorage in orthodontics--a review of various systems in animal and human studies. *International Journal of Oral and Maxillofacial Implants* 23: 75-88
- Kanomi R 1997 Mini-implant for orthodontic anchorage. *Journal of Clinical Orthodontics* 31: 763-767.
- Kim JW, Ahn SJ, Chang YI. 2005 Histomorphometric and mechanical analyses of the drill-free screw as orthodontic anchorage. *American Journal of Orthodontics and Dentofacial Orthopedics* 128: 190-4.
- Klokkevold PR, Han TJ 2007 How do smoking, diabetes, and periodontitis affect outcomes of implant treatment?. *International Journal of Oral and Maxillofacial Implants* 22 Suppl: 173-202.
- Kyung HM, Park HS, Bae SM, Sung JH, Kim IB 2003 Development of orthodontic micro-implants for intraoral anchorage. *Journal of Clinical Orthodontics* 37: 321-8.
- Kyung HM 2006 The Use of Microimplants in Lingual Orthodontic Treatment. *Seminars in Orthodontics* 12: 186-190.
- Le Guéhennec L, Soueidan A, Layrolle P, Amouriq Y 2007 Surface treatments of titanium dental implants for rapid osseointegration. *Dental Materials* 23: 844-54.
- Leung MT, Lee TC, Rabie AB, Wong RW 2008 Use of Miniscrews and Miniplates in Orthodontics. *Journal of Oral and Maxillofacial Surgery* 66: 1461-6.
- Ludwig B 2007 Mini-Implantate in der Kieferorthopaedie - Innovative Verankerungskonzepte. Quintessenz Verlags-GmbH. Berlin.
- McGuire MK, Scheyer ET, Gallerano RL 2006 Temporary anchorage devices for tooth movement: a review and case reports. *Journal of Periodontology* 77: 1613-24
- Mellado-Valero A, Ferrer-García JC, Calvo-Catalá J, Labaig-Rueda C 2010 Implant treatment in patients with osteoporosis. *Medicina Oral Patología Oral y Cirugía Bucal* 15: e52-7.
- Melsen B 2005 Mini-implants: Where are we?. *Journal of Clinical Orthodontics* 39: 539-47.
- Morais LS, Serra GG, Muller CA, Andrade LR, Palermo EF, Elias CN, Meyers M 2007 Titanium alloy mini-implants for orthodontic anchorage: Immediate loading and metal ion release. *Acta Biomaterialia* 3: 331-9.
- Morarend C, Qian F, Marshall SD, Southard KA, Grosland NM, Morgan TA, McManus M, Southard TE 2009 Effect of screw diameter on orthodontic skeletal anchorage. *American Journal of Orthodontics and Dentofacial Orthopedics* 136: 224-9.
- Odman J, Lekholm U, Jemt T, Thilander B 1994 Osseointegrated implants as orthodontic anchorage in the treatment of partially edentulous adult patients. *European Journal of Orthodontics*, 16: 187-201.
- Okazaki Y, Gotoh E, Manabe T, Kobayashi K 2004 Comparison of metal concentrations in rat tibia tissues with various metallic implants. *Biomaterials* 25: 5913-20
- Papadopoulos MA, Tarawneh F 2007 The use of miniscrew implants for temporary skeletal anchorage in orthodontics: A comprehensive review. *Oral Surgery Oral Medicine Oral Pathology Oral Radiology and Endodontology* 103: e6-15.
- Papadopoulos MA 2008 Orthodontic treatment of Class II malocclusion with miniscrew implants. *American Journal of Orthodontics and Dentofacial Orthopedics* 134: 604.e1-16; discussion 604-5.
- Park HS, Jeong SH, Kwon OW 2006 Factors affecting the clinical success of screw implants used as orthodontic anchorage. *American Journal of Orthodontics and Dentofacial Orthopedic* 130: 18-25.
- Park HS, Kwon OW, Sung JH 2004 Micro-implant anchorage for forced eruption of impacted canines. *Journal of Clinical Orthodontics* 38: 297.
- Pienkowski D, Stephens GC, Doers TM, Hamilton DM 1998 Multicycle mechanical performance of titanium and stainless steel transpedicular spine implants. *Spine (Phila Pa 1976)* 23: 782-8.
- Polat-Ozsoy O, Arman-Ozircipici A, Veziroglu F 2009 Miniscrews for upper incisor intrusion. *European Journal of Orthodontics* 31: 412-6.
- Ramos MC, Vinagre S, Cardoso MF 2010 Knowledge, behavior and ethical responsibility of health professionals with regard to smoking. *Revista Portuguesa de Cardiologia* 29: 923-46.
- Roberts WE, Smith RK, Zilberman Y, Mozsary PG, Smith RS 1984 Osseous adaptation to continuous loading of rigid endosseous implants. *American Journal of Orthodontics* 86: 95-111.
- Schnelle MA, Beck FM, Jaynes RM, Huja SS 2004 A radiographic evaluation of the availability of bone for place-

- ment of miniscrews. *Angle Orthodontist* 74: 832-7.
- Sedarat C, Harmand MF, Naji A, Nowzari H 2001 In vitro kinetic evaluation of titanium alloy biodegradation. *Journal of Periodontal Research* 36: 269-74.
- Shapiro PA, Kokich VG 1988 Uses of implants in orthodontics. *Dental Clinics of North America* 32: 539-50.
- Silverstein LH, Koch JP, Lefkove MD, Garnick JJ, Singh B, Steflik DE 1995 Nifedipine-induced gingival enlargement around dental implants: a clinical report. *Journal of Oral Implantology* 21: 116-20.
- Skeggs RM, Benson PE, Dyer F. Reinforcement of anchorage during orthodontic brace treatment with implants or other surgical methods. *Cochrane Database of Systematic Reviews* 2007, Issue3. Art.No: CD005098. DOI:10.1002/14651858. CD00 5098. Pub2.
- Tseng YC, Hsieh CH, Chen CH, Shen YS, Huang IY, Chen CM 2006 The application of mini-implants for orthodontic anchorage. *International Journal of Oral and Maxillofacial Surgery* 35:704-7.
- Turley PK, Kean C, Schur J, Stefanac J, Gray J, Hennes J, Poon LC 1988 Orthodontic force application to titanium endosseous implants. *Angle Orthodontist* 58:151-62
- Umemori M, Sugawara J, Mitani H, Nagasaka H, Kawamura H 1999 Skeletal anchorage system for open-bite correction. *American Journal of Orthodontics and Dentofacial Orthopedics* 115:166-74.
- Wawrzinek C, Sommer T, Fischer-Brandies H 2008 Microdamage in cortical bone due to the overtightening of orthodontic microscrews. *Journal of Orofacial Orthopedics* 69:121-34.
- Wehrbein H, Glatzmaier J, Yildirim M 1997 Orthodontic anchorage capacity of short titanium screw implants in the maxilla. An experimental study in the dog. *Clinical Oral Implants Research* 8:131-41.
- Wilmes B, Ottenstreuer S, Su YY, Drescher D 2008 Impact of implant design on primary stability of orthodontic mini-implants. *Journal of Orofacial Orthopedics* 69: 42-50.
- Wilmes B, Su YY, Sadigh L, Drescher D 2008 Pre-drilling force and insertion torques during orthodontic mini-implant insertion in relation to root contact. *Journal of Orofacial Orthopedics* 69: 51-8.
- Xun C, Zeng X, Wang X 2007 Microscrew anchorage in skeletal anterior open-bite treatment. *Angle Orthodontist* 77: 47-56.
- Yao CC, Lee JJ, Chen HY, Chang ZC, Chang HF, Chen YJ 2005 Maxillary molar intrusion with fixed appliances and mini-implant anchorage studied in three dimensions. *Angle Orthodontist* 75: 754-60.

Internet Links:

- Glossary of Orthodontic Terms: <http://www.bos.org.uk/orthodonticsandyou/Information+for+Patients/glossary>
Αναζήτηση στις 7/12/2011 – Accessed on 7/12/2011
- Latex Allergy Symptoms: <http://www.latexallergyresources.org/symptoms>
Accessed on 7/12/2011

Choice criteria and evolution of dental implants abutments.

Konstantinos S. Pallis¹, Spyridon A. Doukoudakis²

SUMMARY

Nowadays there are at least 20 different abutment connections. The interest is focused mainly at the internal connection. Of course, there are several guidelines, that reduce failure rates. Such guidelines are: good fracture resistance and fit, minimum rotational movement, satisfactory specifications, good occlusal contacts and biocompatibility. These guidelines are much more important for materials, such as the dental ceramics. The newly dental ceramic abutments are mainly made from Alumina or Zirconium. Both types are available in several shapes and connections, internal and external. Even more the internal connection ceramic abutments are divided by the material, at the internal connection, which, sometimes, is metal and, sometimes, is ceramic.

► **Λέξεις-Κλειδιά:** dental implant abutments, external vs internal connection, ceramic implant abutments, implant abutments connection design

INTRODUCTION

In a dental implant treatment, mainly, we have two parts: 1) the *main implant body* and 2) the *implant abutment*, which will support the final prosthesis. The precision of fit at the connection between these two parts is basic for the dental treatment success. There are several new designs of dental implant-abutment contacts. These give solutions at the problems, which existed at the external connection design. Such designs are the conical internal screw, the conical hexagon, the internal octagon, the internal hexagon, the cylindrical hexagon and the Morse taper connection (Figure 1). The geometry of the internal connections is completely different from that

of the external. Sometimes at the internal connection, we have thinner and shorter connection walls and narrower horizontal contact, which can lead to an exposed contact point. On the other hand, the internal contacts offer:

- a) shorter vertical solutions for the prosthetic parts,
- b) internal spread of the lateral external forces,
- c) safety for the internal retention screw and
- d) long internal walls at the connection which give better vertical resistance of the final torquing.

The internal connection reduces vibrations at the main implant body and secures better oral hygiene. It also offers options for the final prosthesis to have better fit and aesthetic results. The internal connection with conical screw abutment initially fabricated from ITI Straumann (Figure 2, Adell, Lekholm et al. 1981). The internal conical connections (Figure 2, point 1) should be machined in order to offer repeatability and precision. This type of connection doesn't have any rotational movement (Figure 2, point 2) and depends on the internal torquing design (Figure 2, point 3), and much more, on the resistance of the internal tapered walls at the dislodging (Figure 2,

¹Prosthodontist, DDS, BMS, MSc

²Assistant Professor of Operative Dentistry, School of Dentistry National and Kapodistrian University of Athens

Correspondence to Konstantinos Pallis

tel. 22940 50502, email: kpallis@yahoo.com

Submitted, January 2012; revised and accepted, May 2012.

• This article is part of the main didactic research of the first writer.




Figure 1. Implant with different implant – abutment connection designs.

point 4). However, some clinical studies have referred screw loosening. Such study showed, that 8.7% of the final prosthesis and 3.7% of the conical abutments screws, have been loosed in a period of six months (Albrektsson, Dahl et al. 1988). Another study, in 3.5 years overall observation, reported screw loosening in 9.1% and fractured screws in 1.5% (Adell, Eriksson et al. 1990). Sutter et al reported that that the preload for the ITI abutments was 124% bigger than that of the initial final torquing (Sutter, Weingart et al. 1994). On the other hand, other studies have showed, that at internal connections with internal walls of 60 and 110, the preload was 80% and 85% respectively of the initial final torquing (Van Steenberghe, Lekholm et al. 1990).

Today the interest is focused at the internal connections, and that's because the internal retention screw offers better internal contacts between abutment and main implant body with the least load. The classical article of Molleresten et al proved the advantages of internal connection (Sones 1989). Specific biological and biomechanical guidelines have to be followed for a successful internal connection. These guidelines are: the satisfactory fracture resistance and sitting, minimum rotational movement, satisfactory occlusion and specific final torquing. Much more these guidelines are required for the all-ceramic materials which offer better aesthetic results.

The first all-ceramic dental abutments were fabricated in 1990 (Zarb and Schmitt 1990). The multiple fractures of these abutments led to the fabrication of new ceramics like Zirconium in 1993 (Jemt and Lekholm 1993). The high fracture strength of this material (Nevins and Langer 1993; Sullivan and Sherwood 1993) established it, in dental implant abutment.

EXTERNAL Vs INTERNAL ABUTMENT IMPLANT CONNECTION

Nowadays more than 20 different geometrical shapes of implant abutment connections exist. The geometry of these parts is important and verifies the

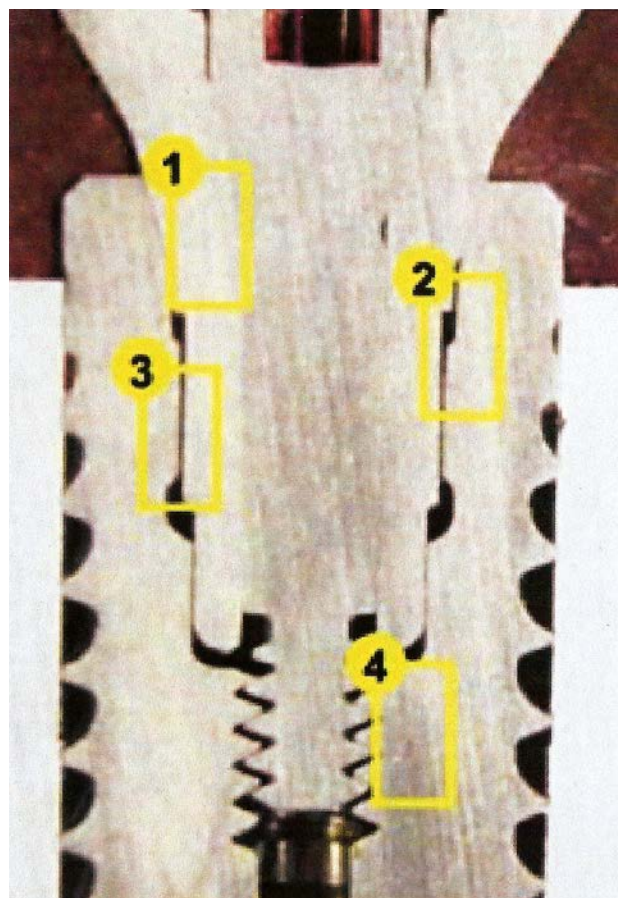


Figure 2. Straumann – ITI implant with the abutment connected at a cross cut section.

load at the contact point, stability and anti-rotational movements. The success of the contact between implant abutment is equal with the stability, that a final prosthesis has over a tooth abutment. Most of the information we have over the implant abutments, according to the international bibliography, are referred to the external hexagon (Figure 3). This is mainly, because the external hexagon was commonly used for complete arch rehabilitation. All the implants were connected with a metallic bar over the external hexagon (Branemark, Hansson et al. 1977; Adell, Le-



Figure 3. External hex by Branemark
(from the website).

kholm et al. 1981). The longevity and the stability of these prostheses depended on the passive fitness of the metal bar according to the basic guidelines of biomechanics. On the other hand, in smaller prostheses and in prostheses of a single tooth, the contact point of the implant-abutment and the torquing screw were exposed to greater load (Rangert, Jemt et al. 1989). In these cases, the screw, that stabilizes the abutment over the implant, is exposed to more lateral forces, which results to screw loosening (Jorneus, Jemt et al. 1992; Haack, Sakaguchi et al. 1995; Rangert, Sullivan et al. 1997). The short and narrow external hex is vulnerable, because of its weaker connection at the implant level, when the final prosthesis is loaded in the mouth (Weinberg 1993; Weinberg and Kruger 1995).

Branemark discovered this disadvantage and suggested a longer external hex of 1.2 mm, so as the final result will have better stability and less rotational movement, especially in single prosthesis. The initial design of 0.7 mm and its clones were used until today, with an only exception of wider and longer hexagons at the intraoral part of the main implant body. Screw loosening has been reported in several cases at a percentage between 6% to 48% (Sones 1989; Zarb and Schmitt 1990; Jemt, Linden et al. 1992; Jemt and Lekholm 1993; Jemt 1994; Kallus and Bessing 1994; Becker and Becker 1995; Wie 1995; Balshi, Hernandez et al. 1996). The results of not having a specific geometry maybe important. In a research of 20 months period with final prosthesis over external hexagon the percentage of screw loosening was 27% for the fix partial dentures and 32% for the removable partial dentures.

The last 10 years, all the manufactures recommend specific final torquing with the use of specific torque drivers. Even though the final torquing is con-

trolled much better, the problem at the connection level exists. Haas et al (Haas, Mensdorff-Pouilly et al. 1995) reported a number of 76 cases with single prosthesis over external hexagon and there was 16% screw loosening at an average period of 22.8 months. In another clinico-statistical study of five years the same researchers reported 9% screw loosening at the last three years. Changes at the height and the width of the external hex have given better clinical results (Binon 1995). Of course several problems still exist. Clinically it is very difficult to place an abutment at a specific position over an external hex and much more at the posterior areas. Maybe this occurs, because of the rotational movement of the abutment over the main implant body, with a subsequent difference at the position of the final prosthesis (Binon 1995). This problem is presented more often in complicated clinical cases with multiple implants. As a result of that, many manufactures have tried to change the design of the external hex and the matching surface of the implant abutment (Binon 1996). These trials lead to the fabrication of wider and longer external hexagons with equivalent prefabricated implant abutments. Two different designs, at the level of the external hexagon and the implant abutment, have been presented so as to reduce the rotational movements. The first change included an increase of 1.5% at the conical shape of the external hexagon with an adjusted small internal contact surface of the implant abutment, which is stabilized over the hexagon with resistance (Swede-Vent TL, Paragon Implant Co, Encino, CA). The second change included anti-rotational grooves at the level of the implant abutment connection, so as to have a better stability over the corners of the external hex (ZR Abutment, Implant Innovations Inc.).

New designs of implant abutment connections resulted in order to overcome the limitations of external hexagon. Such designs were the conical screw, the conical hexagon, the internal octagon, the internal hexagon, the cylindrical hexagon, the conical shape of «Morse taper», the internal locking bar and the internal connection with bending flexibility. Over these designs, the internal octagon type (Omniloc, Sulzer Calcitek) and the elastic bending contact type (IMZ) are not available. The internal octagon, because of its thin walls (0.6 mm) and its shorter diameter, with a geometrical profile similar to a cylinder, offered less rotational movement and less resistance to its function. The bending flexible IMZ connection had an internal part of polymethylmethacrylate, which purpose was to

replace the periodontal membrane and to reduce the load over the implant. Problems that have been presented, lead the manufacturers to new design methods, so as to change the design of the used parts (den Dunnen, Slagter et al. 1997; Behr, Lang et al. 1998).

Mainly two different designs of external connections, except of the hexagon one, are available. The first is the external octagon and the other is with «a key lock» mechanism. The external octagon is a unique design embedded at the main implant body with a diameter of 3.3-3.5 mm (Figure 4) (ITI narrow neck). It is designed specifically for anterior areas of the lower arch. The high resistance octagon connection offers less rotational movement because of its 45° limitation at a rotational movement. The internal connection type (Sulzer Calcitek) is designed with six external parallel keys, which are locked with six internal grooves. This implant design has been fabricated, so as to fracture before the main implant body. Mainly the internal connection has been fabricated in two shapes with three different base diameters. The implant bases of 4 mm and 5 mm have the same geometry and present the same fracture resistance with the least rotational movement (Binon 1996). Overall the geometry of the internal connections is quite different (shorter and thinner horizontal platform). The internal walls of this type of connections reduce the height of the used abutment, the lateral load inside the main implant body, with a secured tightening screw, and resist at the dislodging. With an internal connection, we can have better oral hygiene and a satisfactory prosthetic results.

ITI Straumann has innovated the internal connection. The initial idea came through the need of a mechanical stable, and repeatable implant abutment connection. Much more the advantage of this connection was the placement of the main implant body at the bone crest, so as a second stage surgery can be avoided (Buser, Weber et al. 1990; Buser, Weber et al. 1990). Even though, this type of connection was characterized as Morse taper, the internal inclination of the connection walls was 60°. A real type of Morse taper contact is between 20°-40° and has specific locking characteristics without screw tightening. Of course, there are questions that an implant abutment connection of 80° without tightening screw will be stable. Overall these two stabilization mechanisms have resulted to a strong stable and repeatable connection.

The internal conical connections should be prefabricated, so as to be repeatable and precise. Mainly,

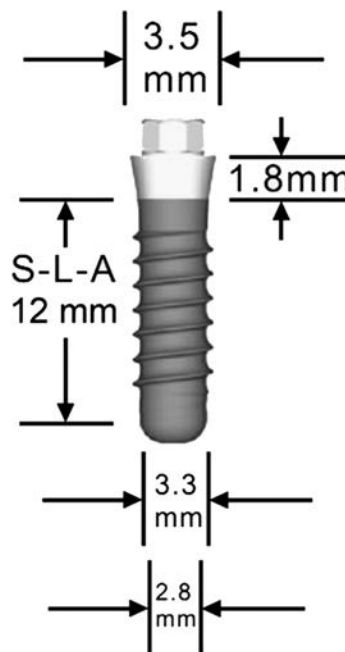


Figure 4. ITI – Straumann narrow neck (from the website).

there are two abutment designs with internal connection from ITI Straumann: a low profile «octagon» (Figure 5) abutment, with a prefabricated abutment cup, which has a finish line at the bevel of the main implant body, and secondly a straight prefabricated abutment, which can be customized according to the final prosthesis. These types of internal connections diminish the rotational movements and that's because there is a key lock at the internal connection and high resistance at the dislodging between the internal walls of the main implant body and the abutment walls. The internal connection protects the retention screw and offers better resistance with less screw loosening. On the other hand screw loosening has been reported in several clinical studies and especially one study has reported screw loosening in a percentage of 9.1% and screw fractures with problems at the implant abutments in a percentage of 1.5% at a period of 3.5 years (Behr, Lang et al. 1998).

Similar contact, between abutment and main implant body, was presented by Astra Tech. This type of connection has 110° conical walls at the connection. The abutment design is also different. It doesn't have any type of connection at the external bevel of the main implant body and the external walls of the abutments have several lengths with a 20° and 45° inclination. This type of design of 110° internal inclination depended on the high resistance, that




Figure 5. ITI external octagon with the fitting castable abutment.

presented at the dislodging. Several differentiations have been reported. Arvidson et al in a study of 517 implant cases at a period of five years reported, that there was no screw loosening or loosening of the final prosthesis without any fracture (Arvidson, Bystedt et al. 1998). Karlsson et al reported complications at the first and second year between a period of two years for 133 implant cases, with fixed and removable prosthesis. The results subsequently were: 4% and 3% screw loosening of the final prosthesis, 2.3% and 0.75% screw loosening of the main abutment and 1.5% fracture prosthesis, at the first year (Karlsson,

Gotfredsen et al. 1998). For single implant prosthesis the abutment design of this type of connection has been differentiated in two parts with a anti-rotational hexagon at the cervical part of it (ST, Astra Tech, Figure 6). The final prosthesis is stabilized with an additional screw. The long internal abutment part offers high resistance at the lateral functional forces. The results of this type of connection were satisfactory and clinical stable (Norton 1997).

This type of abutment design showed 60% greater resistance than that of the initial external connection (Norton 1997). Several theories were conflicted concerning the final torquing load in an internal connection, comparative with the recommended torquing load. Sutter et al reported, that the preload for the ITI Straumann abutment implant connections was greater (124%) than the final torquing load. Also, other studies have showed, that at the abutment implant connections with, 60 and 110, the preload was 80% and 85% subsequently greater than the initial torquing load (Norton 1999).

Nowadays, there are several hexagon abutment implant connections (Figure 7). The initial design has been upgraded with new different and unique contact points. The hexagon abutment implant connections had a similar contact with the internal octagon. This type of design reduced significantly the vertical height of the used sitting area of the final prosthesis,



Figure 6. Implant design by Astra-Tech (from the website).




Figure 7. Internal connection with hexagon design (from the website).

which offered a variety of solutions at the treatment plan. Changes from this design, came from a manufacturer, which fabricated longer hexagon with 10 less inclination. This resulted to a contact with more resistance (Screw Vent TL., Paragon Implant Co).

Several factors such as the narrow platform of 3.5 mm, the internal bevel, the sharp internal contact surfaces, the thin wall of the main implant body at the contact point and the low resistance in pressure, led to fractures at the bone crest, at the height of the implant - abutment connection. Also, occlusion and wrong treatment plan contributed to that result. A study referred, that there was a percentage of 65.2% and 43.5% success at the upper and the lower arch respectively, with an average bone loss of 2.9 mm at a period of seven years (De Bruyn, Collaert et al. 1999). The researchers refer, that the maximum pressure load have been appeared inside the main implant body at the connection level. This load can be transferred to the bone crest, which can explain the observed bone loss (De Bruyn, Collaert et al. 1999). At the implant contacts with diameters of 4.5 mm and 5.7 mm an additional horizontal anchorage, made of copper, had been placed at the bevel of the cervical part of the main implant body. This, with additional wider walls, had occluded to higher fracture resistance.

An optional design of abutment implant connection has been presented. This design had a slippery contact between abutment and implant with a depth of 5 mm inside the main implant body (Frialit-2, Friadent). The internal connection between abutment and the main implant offers: less rotational movement and an amplitude of 60° at the placement



Figure 8. Hermetic Seal, Friadent (from the website).

of the abutment. These abutment designs offer good resistance at the lateral forces, satisfactory vertical resistance and protected retentional screw with a subsequent high resistance at the fracture (Mollersten, Lockowandt et al. 1997). In this type of connection, when there is a problem, the failure is presented only at the final prosthesis and not at the main implant body.

Also this type of abutment implant contact offers satisfactory locking position. At the contact point between abutment and implant, there is silicon, which offers better sealing to microbes (Hermetic Seal, Friadent, Jansen, Conrads et al. 1997, Figure 8). A variety of 3.3 mm, 3.5 mm, 3.8 mm, 4.5 mm, 5.5 mm and 6.5 mm platforms are available, so as to offer high fracture resistance, low rotational movements, low anti-torquing values according to the desired mechanical strategies.

Subsequently with the upper abutment connections, two new designs are available. The first one is fabricated with a long central wall similar to the matching surface of the main implant body. This type of connection offered stability and repeatability at the placement of the cervical wall of the abutment inside the main implant body. The second one, Camlog (Altatec Biotechnologies, Irvine, CA) is an abutment with central connection, mainly available in Europe. The initial design was available for a short time (Figure 9). This type of abutment connection has also long internal walls and has been referred 60% stronger than the internal hexagon connection. Three lateral external slots, of this type of abutment implant connection, offered positioning guides and reduced the rotational movement. The main implant body of



Figure 9. Camlog (Altatec Biotechnologies, Irvine, CA).
–from the website.

Camlog with its abutment, is a hybrid with six loose screw threads at the cervical part of the main implant body. Neither the manufacturer, nor the international bibliography have reported any information relevant to these types of connections recently.

An original abutment implant connection «Morse taper» type has been innovated by Bicon (Boston, MA). This type of connection is stabilized without a retention screw (Figure 10). The cervical part of the used abutment has long contact wall, with an internal inclination of 1o to 2o, which matches with a slippery internal surface of the main implant body. The placement of this abutment can be succeeded with sharp force. Resistance at the dislodging can be fulfilled only if, the matching surfaces, between abutment and main implant body, are dry and clean. The problem, with this type of connection, is the repeatability at the abutment positioning. The flat surface of the external part of the used abutment or the abutments with inclination can cause, several problems, at the final positioning of them. This is much more complicated in multiple implant cases. The manufacturer recommended specific key-locks, at the positioning, so as the positioning of the abutments can be repeatable.

The interest at the abutment implant connection design is focused at the internal connections. The clinical motives, for a successful dental treatment, are: necessary number of placed implants, equivalent diameter and length of these, precise fit of the final prosthesis with short spans and predictable occlusion contacts.

ALL-CERAMIC DENTAL IMPLANT ABUTMENTS

The use of dental implants, in every day dental treatment, is an acceptable and highly predictable treatment solution (Jansen, Conrads et al. 1997; Pje-

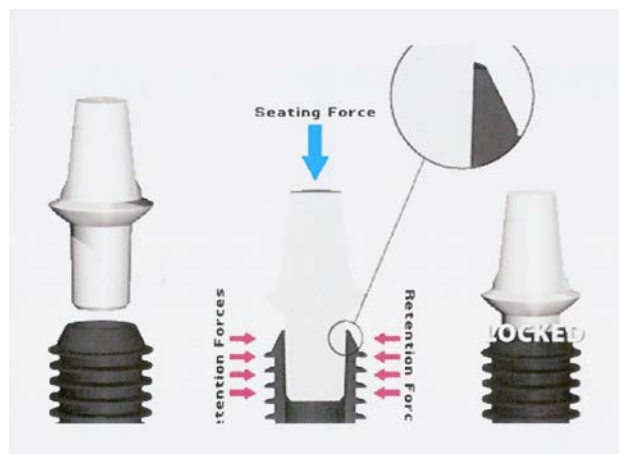


Figure 10. «Morse taper» by Bicon, Boston, MA
(from the website).

tursson, Tan et al. 2004; Pjetursson, Bragger et al. 2007; Jung, Holderegger et al. 2008). The success of this therapeutic scheme depends, also, on the selection of the appropriate dental implant abutments. Initially, the used dental implant abutments were metallic with a high success rate. Subsequently, they have been characterized as «golden analogs» for a prosthetic treatment over dental implants (Andersson, Odman et al. 1995; Pjetursson, Bragger et al. 2007; Sailer, Pjetursson et al. 2007; Sailer, Zembic et al. 2007). Nowadays, more than ever, the aesthetic demands are equal with the functional ones. Both criteria, aesthetic and functional, are considerable for a successful dental treatment.

A basic disadvantage of the metallic dental implant abutments is the discoloration at the implant abutment joint. Several studies have showed this type of discoloration in the oral cavity (Jung, Holderegger et al. 2008; Jung, Pjetursson et al. 2008). On the other hand this discoloration was much less with the use of ceramic dental implant abutments (Jung, Holderegger et al. 2008; Jung, Pjetursson et al. 2008). Additionally, ceramic abutments are less favorable to the oral microbes accumulation (Scarano, Piattelli et al. 2004). Also, the biocompatibility of the dental ceramic abutments is similar with that of the metallic ones (Hashimoto, Akagawa et al. 1988; Abrahamsson, Berglundh et al. 1998; Kohal, Weng et al. 2004). Basic disadvantage of the dental ceramic abutments is the brittle characteristic of this material. This results to a weaker and more vulnerable material at the pressure load phase.

According to these, new dental ceramic abutments have been fabricated. The ceramic base of




Figure 11. The white dots are from zirconium.
The dark grey dots are from alumina.

these materials is mainly fabricated by Alumina or Zirconium (Prestipino and Ingber 1993; Prestipino and Ingber 1993, Figure 11). The Alumina ceramic abutments, in single cases, demonstrated a success rate between 93% to 100% (Andersson, Taylor et al. 2001). Respectively the Zirconium ceramic abutments showed a success rate close to 100% (Glauser, Sailer et al. 2004; Canullo 2007). Additionally, in a three years study, the Zirconium ceramic abutments were used simultaneously with metallic ones, at the posterior region and showed a success rate close to 100% (Zembic, Sailer et al. 2009). According to these results, the Zirconium ceramic abutments are the most common solution in dental implant treatment for aesthetic cases.

The Zirconium ceramic implant abutments are available in several geometrical shapes according to the used matching implant. Also, this type of abutment mainly can be differentiated according to the type of connection, internal or external. Additionally the Zirconium implant abutments have one more differentiation. The matching surfaces of the abutment and the main implant body characterize this differentiation. We have two different type of connections: a) ceramic abutment with metallic internal connection and b) abutment with ceramic internal connection (Sailer, Philipp et al. 2009; Sailer, Sailer et al. 2009, Figure 12).

Several studies (English 1992; Binon 1995; Binon 1996; Binon 1996; Gomez-Roman, Schulte et al. 1997; Guzaitis, Knoernschild et al. 2011) have proved the advantages of the internal connection over the external one. The Zirconium ceramic abutments with metallic internal contact (Figure 12 A, B) have shown




Figure 12. Different design of all-ceramic dental abutment designs (from the website).

greater fracture resistance, than those with ceramic internal contact (Figure 12 C) (Butz, Heydecke et al. 2005; Mitsias, Silva et al. 2010).

Another factor that specifies the strength of a ceramic implant abutment is the thickness of its axial walls (Wang, Aboushelib et al. 2008; Nguyen, Tan et al. 2009). There is a minimum thickness for the Zirconium abutment axial walls, that can be used, so as to achieve a satisfactory fracture resistance (Manicone, Rossi Iommetti et al. 2007). According to these, we have several clinical results and differentiations, which depend not only from the type of internal connection, but also from the dimensions of the abutment matching part (Truninger, Stawarczyk et al. 2012).

CONCLUSIONS

Nowadays, the dentist has multiple implant solutions, so as to satisfy the patient's functional and aesthetic needs. In order these to be achieved, continuing education is needed. This education includes knowledge of the used new techniques and materials, part of these are the implants.

The manufacturing companies offer a wide variety of implant parts for the dental clinician. Education, usability and cost are three factors, that mainly should be considered for a satisfactory dental implant treatment.

The dentist has to be informed for the dental materials evolution. Part of them are the implant parts. A dental implant treatment includes two stages: a) the surgical and b) the prosthetic. At the surgical stage, the dentist has, not only to choose the appropriate main implant body, but also to place it at the wright position in the bone crest. At the prosthetic stage, the selection of the appropriate implant abut-

ments and the design of the final prosthesis, are the main criteria.

The criteria for the dental implant abutment selection are: a) implant position, b) type of implant body, c) final prosthetic design. According to these, the dentist should utilize the appropriate treatment plan for every patient. This can be achieved: with the right knowledge and manipulation of the available implant parts and b) a satisfactory result at the laboratory. The final result depends on several factors, part of them is the selection of the right dental implant abutment and the right use of it both from the dental technician and the dental clinician.

BIBLIOGRAPHY

- Abrahamsson, I., T. Berglundh, et al. (1998). «The mucosal attachment at different abutments. An experimental study in dogs.» *J Clin Periodontol* 25(9): 721-727.
- Adell, R., B. Eriksson, et al. (1990). «Long-term follow-up study of osseointegrated implants in the treatment of totally edentulous jaws.» *Int J Oral Maxillofac Implants* 5(4): 347-359.
- Adell, R., U. Lekholm, et al. (1981). «A 15-year study of osseointegrated implants in the treatment of the edentulous jaw.» *Int J Oral Surg* 10(6): 387-416.
- Albrektsson, T., E. Dahl, et al. (1988). «Osseointegrated oral implants. A Swedish multicenter study of 8139 consecutively inserted Nobelpharma implants.» *J Periodontol* 59(5): 287-296.
- Andersson, B., P. Odman, et al. (1995). «Single-tooth restorations supported by osseointegrated implants: results and experiences from a prospective study after 2 to 3 years.» *Int J Oral Maxillofac Implants* 10(6): 702-711.
- Andersson, B., A. Taylor, et al. (2001). «Alumina ceramic implant abutments used for single-tooth replacement: a prospective 1- to 3-year multicenter study.» *Int J Prosthodont* 14(5): 432-438.
- Arvidson, K., H. Bystedt, et al. (1998). «Five-year prospective follow-up report of the Astra Tech Dental Implant System in the treatment of edentulous mandibles.» *Clin Oral Implants Res* 9(4): 225-234.
- Balshi, T. J., R. E. Hernandez, et al. (1996). «A comparative study of one implant versus two replacing a single molar.» *Int J Oral Maxillofac Implants* 11(3): 372-378.
- Becker, W. and B. E. Becker (1995). «Replacement of maxillary and mandibular molars with single endosseous implant restorations: a retrospective study.» *J Prosthet Dent* 74(1): 51-55.
- Behr, M., R. Lang, et al. (1998). «Complication rate with prosthodontic reconstructions on ITI and IMZ dental implants. Internationales Team fur Implantologie.» *Clin Oral Implants Res* 9(1): 51-58.
- Binon, P. P. (1995). «Evaluation of machining accuracy and consistency of selected implants, standard abutments, and laboratory analogs.» *Int J Prosthodont* 8(2): 162-178.
- Binon, P. P. (1996). «Evaluation of three slip fit hexagonal implants.» *Implant Dent* 5(4): 235-248.
- Binon, P. P. (1996). «The spline implant: design, engineering, and evaluation.» *Int J Prosthodont* 9(5): 419-433.
- Branemark, P. I., B. O. Hansson, et al. (1977). «Osseointegrated implants in the treatment of the edentulous jaw. Experience from a 10-year period.» *Scand J Plast Reconstr Surg Suppl* 16: 1-132.
- Buser, D., H. P. Weber, et al. (1990). «The treatment of partially edentulous patients with ITI hollow-screw implants: presurgical evaluation and surgical procedures.» *Int J Oral Maxillofac Implants* 5(2): 165-175.
- Buser, D., H. P. Weber, et al. (1990). «Tissue integration of non-submerged implants. 1-year results of a prospective study with 100 ITI hollow-cylinder and hollow-screw implants.» *Clin Oral Implants Res* 1(1): 33-40.
- Butz, F., G. Heydecke, et al. (2005). «Survival rate, fracture strength and failure mode of ceramic implant abutments after chewing simulation.» *J Oral Rehabil* 32(11): 838-843.
- Canullo, L. (2007). «Clinical outcome study of customized zirconia abutments for single-implant restorations.» *Int J Prosthodont* 20(5): 489-493.
- De Bruyn, H., B. Collaert, et al. (1999). «Clinical outcome of Screw Vent implants. A 7-year prospective follow-up study.» *Clin Oral Implants Res* 10(2): 139-148.
- den Dunnen, A. C., A. P. Slagter, et al. (1997). «Professional hygiene care, adjustments and complications of mandibular implant-retained overdentures: a three-year retrospective study.» *J Prosthet Dent* 78(4): 387-390.
- English, C. E. (1992). «Externally hexed implants, abutments, and transfer devices: a comprehensive overview.» *Implant Dent* 1(4): 273-282.
- Glauser, R., I. Sailer, et al. (2004). «Experimental zirconia abutments for implant-supported single-tooth restorations in esthetically demanding regions: 4-year results of a prospective clinical study.» *Int J Prosthodont* 17(3): 285-290.
- Gomez-Roman, G., W. Schulte, et al. (1997). «The Frialit-2 implant system: five-year clinical experience in single-tooth and immediately postextraction applications.» *Int J Oral Maxillofac Implants* 12(3): 299-309.
- Guzaitis, K. L., K. L. Knoernschild, et al. (2011). «Effect of repeated screw joint closing and opening cycles on implant prosthetic screw reverse torque and implant and screw thread morphology.» *J Prosthet Dent* 106(3): 159-169.
- Haack, J. E., R. L. Sakaguchi, et al. (1995). «Elongation and preload stress in dental implant abutment screws.» *Int J Oral Maxillofac Implants* 10(5): 529-536.
- Haas, R., N. Mensdorff-Pouilly, et al. (1995). «Branemark single tooth implants: a preliminary report of 76 implants.» *J Prosthet Dent* 73(3): 274-279.
- Hashimoto, M., Y. Akagawa, et al. (1988). «Single-crystal sapphire endosseous dental implant loaded with func-

- tional stress--clinical and histological evaluation of peri-implant tissues.» *J Oral Rehabil* 15(1): 65-76.
- Jansen, V. K., G. Conrads, et al. (1997). «Microbial leakage and marginal fit of the implant-abutment interface.» *Int J Oral Maxillofac Implants* 12(4): 527-540.
- Jemt, T. (1994). «Fixed implant-supported prostheses in the edentulous maxilla. A five-year follow-up report.» *Clin Oral Implants Res* 5(3): 142-147.
- Jemt, T. and U. Lekholm (1993). «Oral implant treatment in posterior partially edentulous jaws: a 5-year follow-up report.» *Int J Oral Maxillofac Implants* 8(6): 635-640.
- Jemt, T., B. Linden, et al. (1992). «Failures and complications in 127 consecutively placed fixed partial prostheses supported by Branemark implants: from prosthetic treatment to first annual checkup.» *Int J Oral Maxillofac Implants* 7(1): 40-44.
- Jorneus, L., T. Jemt, et al. (1992). «Loads and designs of screw joints for single crowns supported by osseointegrated implants.» *Int J Oral Maxillofac Implants* 7(3): 353-359.
- Jung, R. E., C. Holderegger, et al. (2008). «The effect of all-ceramic and porcelain-fused-to-metal restorations on marginal peri-implant soft tissue color: a randomized controlled clinical trial.» *Int J Periodontics Restorative Dent* 28(4): 357-365.
- Jung, R. E., B. E. Pjetursson, et al. (2008). «A systematic review of the 5-year survival and complication rates of implant-supported single crowns.» *Clin Oral Implants Res* 19(2): 119-130.
- Kallus, T. and C. Bessing (1994). «Loose gold screws frequently occur in full-arch fixed prostheses supported by osseointegrated implants after 5 years.» *Int J Oral Maxillofac Implants* 9(2): 169-178.
- Karlsson, U., K. Gotfredsen, et al. (1998). «A 2-year report on maxillary and mandibular fixed partial dentures supported by Astra Tech dental implants. A comparison of 2 implants with different surface textures.» *Clin Oral Implants Res* 9(4): 235-242.
- Kohal, R. J., D. Weng, et al. (2004). «Loaded custom-made zirconia and titanium implants show similar osseointegration: an animal experiment.» *J Periodontol* 75(9): 1262-1268.
- Manicone, P. F., P. Rossi Iommetti, et al. (2007). «An overview of zirconia ceramics: basic properties and clinical applications.» *J Dent* 35(11): 819-826.
- Mitsias, M. E., N. R. Silva, et al. (2010). «Reliability and fatigue damage modes of zirconia and titanium abutments.» *Int J Prosthodont* 23(1): 56-59.
- Mollersten, L., P. Lockowandt, et al. (1997). «Comparison of strength and failure mode of seven implant systems: an in vitro test.» *J Prosthet Dent* 78(6): 582-591.
- Nevins, M. and B. Langer (1993). «The successful application of osseointegrated implants to the posterior jaw: a long-term retrospective study.» *Int J Oral Maxillofac Implants* 8(4): 428-432.
- Nguyen, H. Q., K. B. Tan, et al. (2009). «Load fatigue performance of implant-ceramic abutment combinations.» *Int J Oral Maxillofac Implants* 24(4): 636-646.
- Norton, M. R. (1997). «An in vitro evaluation of the strength of an internal conical interface compared to a butt joint interface in implant design.» *Clin Oral Implants Res* 8(4): 290-298.
- Norton, M. R. (1999). «Assessment of cold welding properties of the internal conical interface of two commercially available implant systems.» *J Prosthet Dent* 81(2): 159-166.
- Pjetursson, B. E., U. Bragger, et al. (2007). «Comparison of survival and complication rates of tooth-supported fixed dental prostheses (FDPs) and implant-supported FDPs and single crowns (SCs).» *Clin Oral Implants Res* 18 Suppl 3: 97-113.
- Pjetursson, B. E., K. Tan, et al. (2004). «A systematic review of the survival and complication rates of fixed partial dentures (FPDs) after an observation period of at least 5 years.» *Clin Oral Implants Res* 15(6): 625-642.
- Prestipino, V. and A. Ingber (1993). «Esthetic high-strength implant abutments. Part I.» *J Esthet Dent* 5(1): 29-36.
- Prestipino, V. and A. Ingber (1993). «Esthetic high-strength implant abutments. Part II.» *J Esthet Dent* 5(2): 63-68.
- Rangert, B., T. Jemt, et al. (1989). «Forces and moments on Branemark implants.» *Int J Oral Maxillofac Implants* 4(3): 241-247.
- Rangert, B. R., R. M. Sullivan, et al. (1997). «Load factor control for implants in the posterior partially edentulous segment.» *Int J Oral Maxillofac Implants* 12(3): 360-370.
- Sailer, I., A. Philipp, et al. (2009). «A systematic review of the performance of ceramic and metal implant abutments supporting fixed implant reconstructions.» *Clin Oral Implants Res* 20 Suppl 4: 4-31.
- Sailer, I., B. E. Pjetursson, et al. (2007). «A systematic review of the survival and complication rates of all-ceramic and metal-ceramic reconstructions after an observation period of at least 3 years. Part II: Fixed dental prostheses.» *Clin Oral Implants Res* 18 Suppl 3: 86-96.
- Sailer, I., T. Sailer, et al. (2009). «In vitro study of the influence of the type of connection on the fracture load of zirconia abutments with internal and external implant-abutment connections.» *Int J Oral Maxillofac Implants* 24(5): 850-858.
- Sailer, I., A. Zembic, et al. (2007). «Single-tooth implant reconstructions: esthetic factors influencing the decision between titanium and zirconia abutments in anterior regions.» *Eur J Esthet Dent* 2(3): 296-310.
- Scarano, A., M. Piattelli, et al. (2004). «Bacterial adhesion on commercially pure titanium and zirconium oxide disks: an in vivo human study.» *J Periodontol* 75(2): 292-296.
- Sones, A. D. (1989). «Complications with osseointegrated implants.» *J Prosthet Dent* 62(5): 581-585.

- Sullivan, D. Y. and R. L. Sherwood (1993). «Considerations for successful single tooth implant restorations.» *J Esthet Dent* 5(3): 118-124.
- Sutter, F., D. Weingart, et al. (1994). «ITI implants in combination with bone grafts: design and biomechanical aspects.» *Clin Oral Implants Res* 5(3): 164-172.
- Truninger, T. C., B. Stawarczyk, et al. (2012). «Bending moments of zirconia and titanium abutments with internal and external implant-abutment connections after aging and chewing simulation.» *Clin Oral Implants Res* 23(1): 12-18.
- Van Steenberghe, D., U. Lekholm, et al. (1990). «Applicability of osseointegrated oral implants in the rehabilitation of partial edentulism: a prospective multicenter study on 558 fixtures.» *Int J Oral Maxillofac Implants* 5(3): 272-281.
- Wang, H., M. N. Aboushelib, et al. (2008). «Strength influencing variables on CAD/CAM zirconia frameworks.» *Dent Mater* 24(5): 633-638.
- Weinberg, L. A. (1993). «The biomechanics of force distribution in implant-supported prostheses.» *Int J Oral Maxillofac Implants* 8(1): 19-31.
- Weinberg, L. A. and B. Kruger (1995). «A comparison of implant/prosthesis loading with four clinical variables.» *Int J Prosthodont* 8(5): 421-433.
- Wie, H. (1995). «Registration of localization, occlusion and occluding materials for failing screw joints in the Branemark implant system.» *Clin Oral Implants Res* 6(1): 47-53.
- Zarb, G. A. and A. Schmitt (1990). «The longitudinal clinical effectiveness of osseointegrated dental implants: the Toronto study. Part III: Problems and complications encountered.» *J Prosthet Dent* 64(2): 185-194.
- Zembic, A., I. Sailer, et al. (2009). «Randomized-controlled clinical trial of customized zirconia and titanium implant abutments for single-tooth implants in canine and posterior regions: 3-year results.» *Clin Oral Implants Res* 20(8): 802-808.

Congenitally missing upper laterals. Clinical considerations –Part I: Orthodontic space closure.

Panagiotis Prevezanos¹, Marina Karamolegkou², Martin Schimmel³, Panagiotis Christou⁴

SUMMARY

Agensis of the maxillary lateral incisors is a common finding with esthetic and functional problems. The treatment options available are space closure by canine substitution and space opening for future prostheses. The aim of this article is to make a report and critical evaluation of the current perspectives treatment options available in the contemporary literature. Clinical cases of each treatment approach are also presented.

Patients with profile pertinent to class 2 with no space problems are ideal candidates for space closure by canine substitution. Ideal intercuspation might be difficult to achieve and some authors might consider the lack of canine guidance a disadvantage. Space closure is suggested to be achieved as soon as possible to avoid periodontal atrophy in the area of the missing laterals, which after space closure in the adult dentition can give unaesthetic black triangles in the anterior region. Space closure seems to be more acceptable by patients although an optimal treatment outcome might require esthetic intervention. The intervention requires enameloplasty reshaping of the premolar to appear as a canine and in certain cases gingivoplasty to give a natural appearance of the soft tissues. Orthodontic treatment could compensate for all the required changes as the ideal placement of the premolar with the ideal root torque can aid the clinician to achieve better results.

The major advantage of this treatment approach is the permanence of the finished result as the overall treatment is completed by the end of orthodontic treatment and the natural dentition is maintained. On the contrary, the tendency of the anterior teeth to reopen and the need for enameloplasty are reported as disadvantages. Factors to be evaluated for the appropriate treatment option are: profile, state of occlusion, degree of crowding or spacing, bilateral or unilateral absence and specific dental factors.

► **Key-Words:** agensis, lateral incisors, maxilla, space opening, reconstruction

INTRODUCTION

Discrepancies in the number of permanent teeth is a common finding varying from total absence of the teeth (anodontia) to congenital absence of only a few teeth (hypodontia or oligodontia in congenital absence of six teeth or more). As a general rule, if only one or a few teeth are missing, the absent tooth will be the most distal tooth of any given type. If a molar tooth is congenitally missing, it is almost always the third molar; if an incisor is missing, it is nearly always the lateral; if a premolar is missing, it almost always is

¹Private practice

²Orthodontist, private practice

³Lecturer, Department of Removable Prosthodontics, University of Geneva, Geneva, Switzerland

⁴Lecturer, Department of Orthodontics, University of Athens, Athens, Greece

Correspondence to Panagiotis Prevezanos
tel. 6940515025, email: zanos@ath.forthnet.gr

Submitted, January 2012; revised and accepted, May 2012.

the second rather than the first. Lower incisors are an exception of this rule (Proffit 2006, Thilander 1985).

One or more third molars are missing in 20–25% of the population. The prevalence of congenital absence of the other teeth varies in different populations. Prevalences around 6% are given for the Scandinavian population with about two per cent each for mandibular premolars, maxillary premolars and maxillary lateral incisors (Thilander 1985).

The treatment options include space opening or closure of the spaces which are a result of the congenitally missing lateral incisors. The present review refers to the orthodontic space closure. This treatment approach includes orthodontic treatment with fixed appliances for closing of the spaces and replacing the congenitally missing maxillary lateral incisors by the canines and the canines by the first premolars, respectively. It is a common and popular approach which can lead to very esthetic and satisfying results nowadays with the aid of esthetic and restorative dentistry. The most difficult task in substituting canines for missing lateral incisors is the achievement of an excellent esthetic and functional outcome that resembles an intact natural dentition.

INDICATIONS AND CONTRAINDICATIONS

Orthodontic space closure may be indicated or contraindicated, after the evaluation of the factors below. Important considerations are:

- Profile
- Malocclusion
- Degree of crowding or spacing
- Size, shape and color of the teeth
- Bilateral or unilateral absence
- Smile line.

Particularly, these factors are:

Profile

A careful examination must be done so the profile type is evaluated, apart from the occlusal type. In general, a balanced, relatively straight profile does not influence the decision of the appropriate treatment plan.

A patient with mildly convex profile with no contraindications for space closure is preferred to be treated by canine substitution. Especially, when there is a little growth potential and overjet reduction by retraction of the central incisors will be used to camouflage a skeletal problem. However, space closure in a patient with moderately convex profile, retru-

sive mandible and a deficient chin prominence may not be the best option. A better alternative may be one that addresses not only the dental malocclusion but the facial profile as well, such as orthognathic surgery. Patients with concave profile type present midface deficiency and/or mandibular prognathism. If the treatment plan is canine substitution of the missing maxillary lateral incisors, this may increase profile concavity and maxillary deficiency. So, these patients should be treated by space opening for prostheses (Araujo et al. 2006, Kinzer and Kokich 2005).

Malocclusion

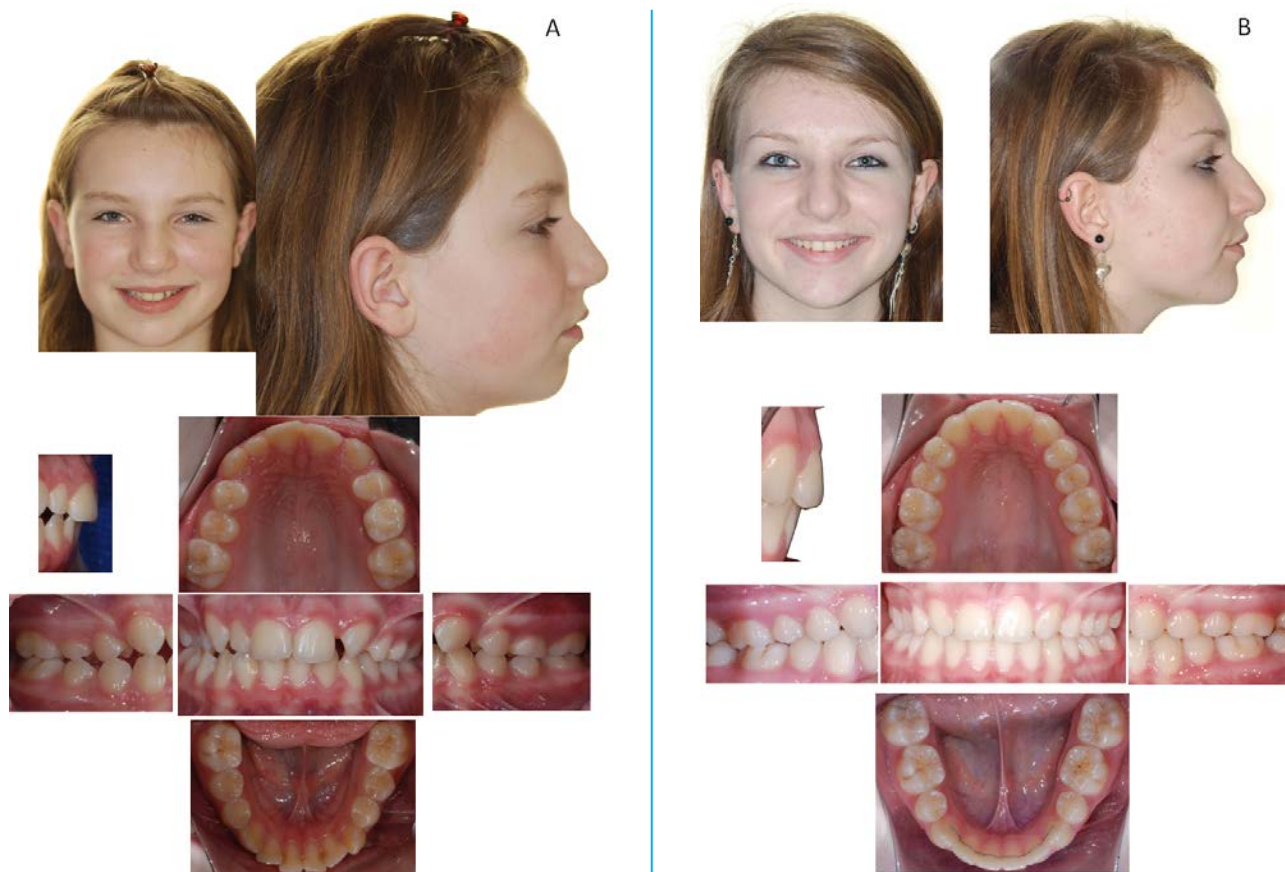
Angle Class II malocclusion with maxillary prognathism is considered as an obvious indication for space closure. In this occlusal pattern, the molar relationship remains Class II and the first premolars are located in the traditional canine position. A Class I malocclusion with sufficient crowding where mandibular extractions are required is also an indication for space closure (Kokich and Kinzer, 2005). Generally, whenever teeth of the mandibular arch need to be extracted for orthodontic reasons, such as severe crowding or protrusion, space closure is the suitable option.

Another indication is a patient with full-lip profile when anterior teeth are severely protruded, or tipped labially or a patient with a balanced profile with normally inclined anterior teeth and minimal or no space available in the maxillary arch (Sabri, 1999). When there is generalized spacing in the arch, closing the spaces is not indicated, but on the contrary, when crowding is present, space closure is the suitable option.

The congenital absence of lateral incisors in Class III malocclusions is generally considered as a contraindication for orthodontic space closure, especially in patients with retrognathic profile type. These cases usually have an edge-to-edge or negative overjet which may be worsen if the spaces are closed as the maxillary arch contracts.

Size, shape and color of the teeth

Normally, the canine is a longer and larger tooth, mesiodistally and labiolingually, than the lateral incisor it is to replace (Bishara et al. 1989), and the first premolar is shorter and narrower than the canine. These differences can create an unattractive periodontal profile with too long and too large mesiodistally 'lateral incisors', and too short and too small 'canines', respectively. Moreover, the natural canine



Case I. Patient with congenitally missing lateral. Extraction of the conoid 12 and orthodontic space closure was performed.

is usually darker and more yellowish than the intact central incisor and its color should be addressed and approximate that of the central incisor, which can be achieved by at-home or in-office vital bleaching (Rosa and Zachrisson 2001, Kokich and Kinzer 2005, Araujo et al. 2006, Brough et al. 2010).

Unilateral absence

These cases seem to be more difficult to manage than the bilateral absence because it is not easy to achieve a midline symmetry which contributes to better dental harmony. In addition, the contralateral incisor is often peg-shaped or diminutive with a thin and short root which causes size discrepancy between the anterior teeth (Gomes et al. 2010). In such circumstances, extraction of the contralateral incisor and normal space closure may be a better option as it facilitates the maintenance of midline and dental symmetry of the maxilla (Rosa and Zachrisson 2001, Savarrio and McIntyre 2005, Kinzer and Kokich 2005, Araujo et al. 2006).

Smile line

In a patient with a high smile line, the demand on esthetic result is enhanced as the gingival levels are more visible. These patients should be treated with orthodontic space closure, as it results to an esthetically more attractive outcome, and should not be treated with space reopening and lateral incisor implant placement, especially young patients. It is unconceivable that such a technique can achieve the long-term occlusal, gingival, and periodontal results in the esthetic zone that are seen with space closure (Kinzer and Kokich 2005, Araujo et al. 2006, Rosa and Zachrisson 2007).

ADVANTAGES

The major advantage of space closure is the permanence of the finished result. This is a one-shot therapy, which means that the overall treatment can be completed by the end of orthodontic treatment at an early age with a permanent result and long-term stability. The alveolar bone height in the actual region

is maintained by the early mesial movement of the canine. The individual keeps his natural dentition which means that lifelong prosthetic restorations, that are likely to need repairs or replacements in the future, are avoided. Thus, the total cost of treatment is reduced for patient's benefit (Armbruster et al., 2005, Rosa and Zachrisson 2007). In addition, clear and natural gingival margin is achieved which will change in synchrony with the patient's own teeth over a lifetime and any change due to the normal aging or for other reasons (mechanical, including tooth-brushing, or periodontal) will take on a natural look (Theytaz and Kiliaridis 2008, Rosa and Zachrisson 2001, 2007).

The esthetic result of space closure as a treatment option in patients with congenitally missing maxillary lateral incisors is generally preferred by general dentists, orthodontists, combined dental specialists, and laypeople. An interesting point was that a significant percentage of general dentists would restore the missing lateral incisors with implants for esthetic reasons but, even those professionals who felt the missing teeth should be restored, many did not prefer the esthetic result of a restored option (Armbruster et al. 2005a,b).

In another study, Robertsson and Mohlin (2000) evaluated the satisfaction of fifty treated patients with lateral incisor agenesis. They have shown that (a) patients treated by space closure were more satisfied with the treatment results than the prosthesis patients, (b) there was no difference between the 2 groups in prevalence of signs and symptoms of temporomandibular junction (TMJ) dysfunction, and (c) patients with prosthetic replacements had impaired periodontal health with accumulation of plaque and gingivitis.

DISADVANTAGES

The tendency of the anterior teeth to reopen and relapse, after the orthodontic treatment is completed, is considered as the main disadvantage (Sabri 1999, Rosa and Zachrisson 2001, 2007, Zachrisson 2007). However, this can be overcome with long-term fixed retention with a palatally bonded flexible spiral wire retainer on the palatal surfaces of the six anterior teeth.

Another disadvantage of this treatment option is the enameloplasty which is required usually on both the canine and premolar in order to resemble the teeth they substitute (Armbruster et al. 2005a,b). Moreover, the color difference between incisors and

canines, can cause esthetic problems and requires restoration. In addition, the fact that canine-protected occlusion is not feasible with space closure is considered as a disadvantage by certain authors, due to the stress placed on the premolars (Sabri 1999). Though, long-term occlusal and periodontal studies have shown there is no evidence for establishment of Class I canine relationship and space closure with premolar substitution for canines can lead to an acceptable functional relationship with modified group function on the working side (Robertsson and Mohlin 2000).

CONCLUSION

Orthodontic space closure is a valid treatment option in cases of congenitally missing maxillary lateral incisors and depends on the evaluation of profile, state of occlusion, and the available space.

- Mildly convex profile
- Class II malocclusion
- A tendency towards maxillary crowding in a patient with a well-balanced profile and normally inclined anterior teeth
- Marked mandibular crowding or protrusion
- Canines and premolars of similar size
- Dentoalveolar protrusion.

REFERENCES

- Araújo EA, Oliveira DD, Araújo MT. Diagnostic protocol in cases of congenitally missing maxillary lateral incisors. *World J Orthod* 2006; 7:376-388.
- Armbruster PC, Gardiner DM, Whitley JB, Flerra J. The congenitally missing maxillary lateral incisor. Part 1: Esthetic judgment of treatment options. *World J Orthod* 2005; 6:369-375.
- Armbruster PC, Gardiner DM, Whitley JB, Flerra J. The congenitally missing maxillary lateral incisor. Part 2: Assessing dentist's preferences for treatment. *World J Orthod* 2005; 6:376-381.
- Bernard JP, Schatz JP, Christou P, Belser U, Kiliaridis S. Long-term vertical changes of the anterior maxillary teeth adjacent to single implants in young and mature adults. A retrospective study. *J Clin Periodontol* 2004; 31:1024-1028.
- Bishara SE, Jakobsen JR, Abdallah EM, Fernandez Garcia A. Comparisons of mesiodistal and buccolingual crown dimensions of the permanent teeth in three populations from Egypt, Mexico, and the United States. *Am J Orthod Dentofacial Orthop*. 1989 Nov; 96(5):416-422.
- Bishop K, Addy L, Knox J. Modern restorative management of patients with congenitally missing teeth: 1. Introduction, terminology and epidemiology. *Dent Update* 2006; 33:531-537.

- Bishop K, Addy L, Knox J. Modern restorative management of patients with congenitally missing teeth: 2. Orthodontic και restorative considerations. *Dent Update* 2006; 33:592-595.
- Bishop K, Addy L, Knox J. Modern restorative management of patients with congenitally missing teeth: 3. Conventional και restorative options και considerations. *Dent Update* 2007; 34:30-38.
- Bishop K, Addy L, Knox J. Modern restorative management of patients with congenitally missing teeth: 4. The role of implants. *Dent Update* 2007; 34:79-84.
- Brough E, Donaldson AN, Naini FB. Canine substitution for missing maxillary lateral incisors: the influence of canine morphology, size, και shade on perceptions of smile attractiveness. *Am J Orthod Dentofacial Orthop*. 2010 Dec; 138(6):705.e1-9; discussion 705-707.
- Buser D, Martin W, Belser UC. Optimizing esthetics for implant restorations in the anterior maxilla: anatomic και surgical considerations. *Int J Oral Maxillofac Implants*. 2004; 19 Suppl:43-61.
- Chiapasco M, Casentini P, Zaniboni M. Bone augmentation procedures in implant dentistry. *Int J Oral Maxillofac Implants*. 2009; 24 Suppl:237-259.
- Czochrowska EM, Stenvik A, Album B, Zachrisson BU. Autotransplantation of premolars to replace maxillary incisors. A comparison with natural incisors. *Am J Orthod Dentofacial Orthop* 2000; 118:592-600.
- Czochrowska EM, Stenvik A, Bjercke B, Zachrisson BU. Outcome of tooth transplantation: survival και success rates 17-41 years posttreatment. *Am J Orthod Dentofacial Orthop* 2002; 121:110-119.
- Czochrowska EM, Stenvik A, Zachrisson BU. The esthetic outcome of autotransplanted premolars replacing maxillary incisors. *Dent Traumatol* 2002; 18:237-245.
- Gomes RR, da Fonseca JA, Paula LM, Faber J, Acevedo AC. Prevalence of hypodontia in orthodontic patients in Brasilia, Brazil. *Eur J Orthod*. 2010 Jun; 32(3):302-6.
- Kern M. Clinical long-term survival of two-retainer και single-retainer all-ceramic resin-bonded fixed partial dentures. *Quintessence Int*. 2005 Feb; 36(2):141-147.
- Kinzer GA, Kokich VO. Managing congenitally missing incisors. Part I: Canine substitution. *J Esthet Restor Dent*. 2005; 17:5-10.
- Kinzer GA, Kokich VO. Managing congenitally missing incisors. Part II: Tooth-supported restorations. *J Esthet Restor Dent*. 2005; 17:76-84.
- Kinzer GA, Kokich VO. Managing congenitally missing incisors. Part III: Single-tooth implants. *J Esthet Restor Dent*. 2005; 17:202-210.
- Kokich VG. Maxillary lateral incisor implants: planning with the aid of orthodontics. *Int J Oral Maxillofac Surg* 2004; 62:48-56.
- Kristerson L. Autotransplantation of human premolars. A clinical και radiographic study of 100 teeth. *Int J Oral Surg*. 1985 Apr; 14(2):200-213.
- Magne P, Magne M, Belser UC. Adhesive restorations, centric relation, και the Dahl principle: minimally invasive approaches to localized anterior tooth erosion. *Eur J Esthet Dent*. 2007; 2(3):260-73.
- McNeill RW, Joondeph DR. Congenitally absent maxillary lateral incisors: treatment planning considerations. *Angle Orthod*. 1973 Jan; 43(1):24-29.
- Nordquist GG, McNeill RW. Orthodontic vs. restorative treatment of the congenitally absent lateral incisor-long term periodontal και occlusal evaluation. *J Periodontol*. 1975 Mar; 46(3):139-143.
- Odman J, Grondahl K, Lekholm U, Thilander B. The effect of osseointegrated implants on the dento-alveolar development. A clinical και radiographic study in growing pigs. *Eur J Orthod* 1991; 13(4):279-286.
- Olsen TM, Kokich VG. Postorthodontic root approximation after opening space for maxillary lateral incisor implants. *Am J Orthod Dentofacial Orthop* 2010; 137:158.e1-158.e8.
- Proffit WR. Classification και aetiology of malocclusion. In Proffit WR, Fields HW, Sarver DM. *Contemporary Orthodontics*, St. Louis, Mosby Inc., 135-136, 2006.
- Robertsson S, Mohlin B. The congenitally missing upper lateral incisor. A retrospective study of orthodontic space closure versus restorative treatment. *Eur J Orthod* 2000; 22:697-710.
- Rosa M, Zachrisson BU. Integrating esthetic dentistry και space closure in patients with missing maxillary lateral incisors. *J Clin Orthod* 2001; 35:221-234.
- Rosa M, Zachrisson BU. Integrating space closure και esthetic dentistry in patients with missing maxillary lateral incisors. *J Clin Orthod* 2007; 41:563-573.
- Sabri R. Management of missing maxillary lateral incisors. *J Am Dent Assoc* 1999; 130:80-84.
- Savarrio L, McIntyre GT. To open or to close space-That is the missing lateral incisor question. *Dent Update* 2005; 32:16-25.
- Slagsvold O, Bjercke B. Applicability of autotransplantation in cases of missing upper anterior teeth. *Am J Orthod*. 1978 Oct; 74(4):410-421.
- Spear FM, Mathews DM, Kokich VG. Interdisciplinary management of single-tooth implants. *Semin Orthod* 1997 Mar; 3(1):45-72.
- Theytaz GA, Kiliaridis S. Gingival και dentofacial changes in adolescents και adults 2 to 10 years after orthodontic treatment. *J Clin Periodontol*. 2008 Sep; 35(9):825-830.
- Thilander B. Classification και aetiology of malocclusion. In: Thilander B., Ronning O. (Eds.) *Introduction to orthodontics* (editors) Stockholm, pp 77-78, 1985.
- Thilander B, Ödman J, Jemt T. Single implants in the upper incisor region και their relationship to the adjacent teeth; an 8- year follow-up study. *Clin Oral Impl Res* 1999; 10:346-355.
- Thilander B, Odman J, Lekholm U. Orthodontic aspects of the use of oral implants in adolescents: a 10-year follow-up study. *Eur J Orthod* 2001 Dec; 23(6):715-731.

- Thilander B. Orthodontic space closure versus implant placement in subjects with missing teeth. *J Oral Rehabil* 2008; 35 Suppl 1:64-71.
- Verzijden CW, Creugers NH, van't Hof MA. Treatment times for posterior resin-bonded bridges. *Community Dent Oral Epidemiol.* 1990 Dec; 18(6):304-308.
- Zachrisson BU, Stenvik A, Haanaes HR. Management of missing maxillary anterior teeth with emphasis on autotransplantation. *Am J Orthod Dentofacial Orthop* 2004; 126:284-288.
- Zachrisson BU. Improving the esthetic outcome of canine substitution for missing maxillary lateral incisors. *World J Orthod* 2007; 8:72-79.

Congenitally missing upper laterals. Clinical considerations –Part II: Prosthodontic options.

Panagiotis Prevezanos¹, Marina Karamolegkou², Martin Schimmel³, Garavaglia Giovanni⁴, Panagiotis Christou⁵

SUMMARY

Agenesis of the maxillary lateral incisors is a common finding with esthetic and functional problems. The treatment options available are space closure by canine substitution and space opening for future prostheses. The aim of this article is to report and evaluate the current treatment options available in the contemporary literature. Clinical cases of each treatment approach are also presented. Space closure by canine substitution seems to be more acceptable by patients although an optimal treatment outcome might require esthetic restoration. The major advantage of this treatment approach is the permanence of the result as the overall treatment is completed by the end of orthodontic treatment and the natural dentition is maintained. On the contrary, the tendency of the anterior teeth to reopen and the need for enameloplasty are reported as disadvantages. On the other hand, the ideal intercuspation of the canine through first premolars and the fact that the teeth are maintained in their natural position in the dental arch are the main advantages of space opening for prosthetic restorations. The major disadvantage is the placement of a lifelong prosthesis in the anterior esthetic zone.

The prosthodontic options are numerous. Bonded bridges are state of the art in conservative dentistry giving a solution to the problem in younger ages, and implants or more extensive bridges can be used when a more permanent solution is sought. The main disadvantage of full jacket bridges is the extensive dental tissue consumption required for their preparation, while the more conservative implants may present vertical discrepancies in relation to the adjacent teeth.

Factors to be evaluated for the choice of the appropriate treatment plan are: patients profile, condition of occlusion, degree of crowding or spacing, bilateral or unilateral absence and other specific dental factors. Another treatment option could be autotransplantation of premolars in the place of the missing laterals. This is feasible only in young patients as the procedure requires developing premolar roots with open apices which promotes tooth integration and periodontal healing.

Conclusion: There is a variety of solutions in the hands of the practitioner. Final decision should be made after careful evaluation of each case without bias to satisfy esthetics, functional and patient's requirements.

► **Key-Words:** agenesis, lateral incisors, maxilla, space closure, reconstruction

¹Private practice, ²Orthodontist, private practice, ³Lecturer, Department of Removable Prosthodontics, University of Geneva, ⁴Lecturer, Department of Fixed Prosthodontics, University of Geneva, ⁵Lecturer, Department of Orthodontics, University of Athens
Correspondence to Panagiotis Prevezanos
tel. 6940515025, email: zanos@ath.forthnet.gr
Submitted, January 2012; revised and accepted, May 2012.

INTRODUCTION

When a patient with agenesis of maxillary lateral incisors visit an orthodontist, then he faces a therapeutic dilemma: closure of the spaces due to agenesis of the lateral incisors or space opening for prosthetic restorations. Important difference of the restorations in the anterior region of the upper jaw is the high

esthetic demands, making the selection and performance of the most appropriate type of restoration difficult, while an additional factor is the conservation of tooth structure. Therefore, create-space management for prosthetic restorations in the region of missing lateral incisors is needed. By this option, all the teeth are maintained in their natural position in the dental arches and the lateral incisors are replaced by prosthetic restorations.

INDICATIONS AND CONTRAINDICATIONS

As for space closure, the orthodontist has to evaluate the same factors so as to proceed to space opening procedure in a patient with congenitally missing lateral incisors.

Profile

Patients with concave profile type usually have an edge-to-edge or a negative overjet and present mid-face deficiency and/or mandibular prognathism. If upright maxillary incisors need to be protruded, or tipped labially, to correct anterior crossbites or to gain upper lip support, space opening is indicated as this will improve the midface deficiency (Sabri 1999, Araujo et al. 2006).

Occlusion

Class III malocclusion is regarded as an inarguable indication for space opening and prosthetic restorations for the missing lateral incisors as this can camouflage the existing malocclusion. This will effect also in the possible midface discrepancy that usually co-exists in this type of malocclusion. Where the skeletal discrepancy is not severe, the space opening procedure may produce a stable Class I incisor relationship at the end of treatment, if sufficient overbite is present (Rosa and Zachrisson 2001, Savarrio and McIntyre 2005, Araújo et al. 2006).

Orthodontic space opening is also indicated when there is no significant malocclusion or normal intercuspation of the posterior teeth, as it will maintain an Angle Class I occlusal type (Sabri 1999). Finally, when pronounced spacing is present in the maxilla, space opening is the treatment of choice (Sabri 1999, Rosa and Zachrisson 2001, Savarrio and McIntyre 2005).

ADVANTAGES

Space opening for missing maxillary incisors favors an ideal intercuspation of canines through first premolars and as a result this is marked as an advan-

tage both functionally and occlusally (McNeill and Joondeph 1973, Nordquist and McNeill 1975, Sabri 1999). These teeth are maintained in their natural position within the dental arch with their natural morphology. In addition, if the treatment plan includes a single tooth implant, the natural teeth remain totally untouched. Finally, the orthodontic treatment is generally shorter in contrast with orthodontic space closure (Sabri 1999, Armbruster et al 2005a,b).

DISADVANTAGES

The major disadvantage of this treatment option is that it commits the patient to a lifelong prosthesis in the most visible area of the mouth where tooth shade and transparency, gingival color, contour and margin levels are critical and difficult to control, particularly in the long term (Sabri 1999, Rosa and Zachrisson 2001, Armbruster et al. 2005a,b).

Furthermore, the overall treatment is not complete when the orthodontic treatment ends. This means, particularly in adolescent patients, that the patient needs long-term retention of the spaces with temporary retainers until all skeletal growth is complete and tooth eruption has ceased, so he or she is eligible for permanent restoration. In addition, all the additional expenses for the permanent restoration and its lifelong maintenance are marked as a disadvantage (Verzijden et al. 1990, Rosa and Zachrisson 2001, Armbruster et al. 2005a,b).

PROSTHETIC OPTIONS

Resin-bonded fixed partial denture

These tooth-supported restorations are considered to be the most conservative as they leave the adjacent teeth relatively untouched. The 5-year survival rate of this type of restoration is up to 67,3%, with debonding being the most common cause of failure (Kern 2005). The factors to be considered for the placement of this restoration include the position, mobility, thickness, and translucency of the abutment teeth as well as the overall occlusion (fig. 1). Occlusal parafunction is a contraindication for these restorations because the occlusal forces are often greater than can be withstood by the resin bond, increasing the risk of debonding (Kern 2005, Kinzer and Kokich 2005, Bishop et al. 2007, Magne et al. 2007).

Cantilevered fixed partial denture

Cantilevered fixed partial denture is the second most conservative restoration and in contrast with

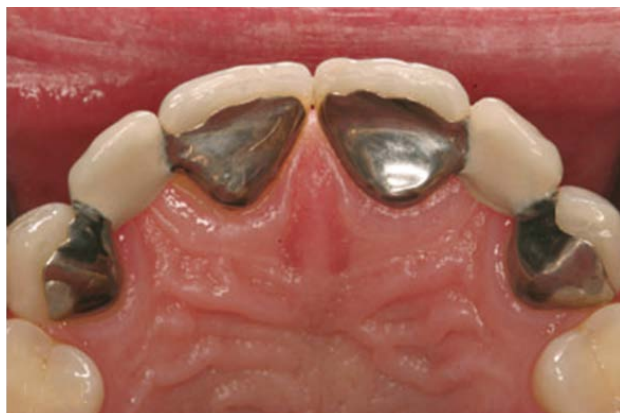

Fig. 1. Rehabilitation after orthodontic space opening with bonded bridges.

the resin-bonded fixed partial denture, the success of this type of restoration is not dependent on the amount of proclination or mobility of the abutment teeth. The 5-year survival rate is 92,3% (Kern 2005). The canine is an ideal abutment for such a restoration due to its root length and crown dimensions. Long-term success of the cantilevered fixed partial denture can be achieved if all contacts in excursive movements are removed from the cantilevered (Kern 2005, Kinzer and Kokich 2005, Savarrio and McIntyre 2005, Bishop et al. 2007, Magne et al. 2007).

Conventional full-coverage fixed partial denture

This is the least conservative of all tooth-supported restorations and it is considered as the treatment of choice when replacing an existing fixed partial denture or when the adjacent teeth require restoration for structural reasons or to alter the facial esthetics. The control of the occlusion and occlusal forces is an advantage of this prosthetic option but, on the other hand, the amount of tooth preparation needed is the main disadvantage, especially in young patients. (Kinzer and Kokich 2005, Bishop et al 2007a).

Single-tooth implant

Single-tooth implant has become a very popular restoration nowadays as it is the most conservative prosthetic option. One of the main advantages is the ability to leave the adjacent teeth totally untouched. In addition, such restorations have shown high success rates with successful osseointegration but maxillary lateral incisor implants are challenging aesthetically. However, there are some thoughts to be evaluated if implant-supported crowns are to be placed (Kokich 2004, Kinzer and Kokich 2005).

1- Implant site development.

When agenesis of maxillary lateral incisors is diagnosed in a young patient, usually primary maxillary lateral incisors are retained. In such cases, it may be necessary to selectively extract the primary lateral incisors to encourage the permanent canine to erupt mesially, adjacent to the central incisor. The canine will influence the thickness of the edentulous alveolar ridge due to its large buccolingual width; otherwise the osseous ridge will not fully develop due to the absence of the lateral incisor.

As the canine is moved distally to open space for the lateral incisor implant and crown, the root movement creates an increased and adequate alveolar ridge which allows proper implant placement. However, the time of implant placement should be relative close to the orthodontic treatment. This procedure is called “*Implant site development*” (Spear et al. 1997, Kokich 2004). If inadequate alveolar ridge is present, ridge augmentation may be necessary using bone grafts (Kokich 2004, Kinzer and Kokich 2005, Savarrio and McIntyre 2005, Bishop et al. 2007b, Chiapasco et al. 2009).

2- Clinical aspects

Adequate implant space. The amount of space needed for the implant and crown is generally determined by the contralateral lateral incisor. However, if both lateral incisors are missing or the contralateral one is peg-shaped, the amount of space should be determined by one of the methods below:

1. The golden proportion
2. The Bolton analysis
3. A diagnostic wax-up (Kinzer and Kokich 2005).

Generally, the adequate coronal space should be no less than 6,3 mm where as the interradicular space no less than 5,7 mm (Olsen and Kokich 2010). At least, 1 mm between of the implant and adjacent roots is desirable as it is cited that narrower distances between them are more likely to show a reduction in bone height over time (Buser et al. 2004, Kokich 2004, Kinzer and Kokich 2005). In addition, fixed retention is suggested rather than removable appliances to prevent relapse.

When the orthodontist opens space for the missing lateral incisor with fixed appliances, he should be very careful so the central incisor and the canine are moved by... and not to tip apart, because this is likely to make implant placement impossible. Thus, the orthodontist must confirm the ideal root position with a periapical or a panoramic radiograph, before the

fixed appliances are removed (Kokich 2004, Kinzer and Kokich 2005).

In certain patients, it may be impossible to achieve acceptable interradicular spacing, even though the coronal spacing may be ideal. Particularly, in a patient with a Class III tendency malocclusion who requires proclination of the maxillary central incisors, when the crowns are tipped labially, the roots tend to converge toward each other resulting in a “wagon-wheel” effect. In such cases, an alternative restoration option is required (Kinzer and Kokich 2005).

Time of implant placement. Generally, implants must not be placed until the patients have completed their facial growth and the majority of their tooth eruption (Odman et al. 1991, Thilander et al. 1999, Thilander 2008). As the face grows and the mandibular rami lengthen, teeth must erupt to remain in occlusion. However, the implant behaves like an ankylosed tooth and will not follow the changes of the alveolar processes due to the eruption of adjacent teeth (Odman et al. 1991, Thilander et al. 1999).

This may result in clinical infraocclusion of the implant-supported crown and cause a discrepancy in the occlusal plane and between the gingival margins of the implant and the adjacent natural teeth (Thilander et al. 1999, Thilander et al. 2001, Bernard et al. 2004, Thilander 2008). Thus, evaluation of the completion of facial growth by cephalometric radiographs must be done and subsequently, the patient should be informed for the optimal time of implant placement (Kokich 2004, Kinzer and Kokich 2005, Bishop et al. 2007a,b). However, even mature adults can exhibit major vertical steps after anterior restorations with implants to the same extent as adolescents (Bernard et al. 2004).

Autotransplantation

Autotransplantation is an interesting treatment alternative in patients with congenitally missing maxillary lateral incisors where the developing premolars are mainly used as autotransplanted teeth. Esthetic improvement of the transplants is necessary (Slagvold and Bjercke 1978, Czochrowska et al. 2000, Czochrowska et al. 2002a,b).

The optimal time for autotransplantation of premolars in the maxillary lateral incisors region is when the root development has reached two thirds to three fourths of the final root length. Possible complications refer to ankylosis, failure of the transplant, and pulpal necrosis. The root growth continues and the prognosis for complete periodontal healing at this

stage of root development is better than 90% (Kristerson 1985). After the transplantation of the tooth, a normal periodontal ligament is established and it can be moved orthodontically like any other tooth that has erupted into occlusion (Zachrisson et al. 2004).

CONCLUSION

The two most common treatment options in patients with congenitally missing maxillary lateral incisors are space closure by canine substitution and space opening for reconstruction. The main points are:

- Both treatment alternatives have advantages and disadvantages as well as indications and contraindications for each one.
- Orthodontic space closure has become a more popular treatment choice as it seems to be more acceptable by patients and periodontically better.
- Space opening for prosthetic replacement is generally not preferred because the esthetic result is difficult to control in long-term.

The choice of autotransplantation has a good esthetic result and it is feasible only in young patients where the roots of premolars are still developing. An interesting alternative includes anterior closure of the spaces, with the canines into the lateral incisors' position, and posterior space opening for single-tooth implants in the premolars' region, where restorations do not need to meet the same strict esthetic requirements.

The choice of the appropriate treatment plan should be a result of careful examination, where each individual is evaluated as a separate case without personal opinions and biases, and should meet the individual expectations which can lead to the desired aesthetic, functional and biological effects.

REFERENCES

- Araújo EA, Oliveira DD, Araújo MT. Diagnostic protocol in cases of congenitally missing maxillary lateral incisors. *World J Orthod* 2006; 7: 376-388.
- Armbruster PC, Gardiner DM, Whitley JB, Flerra J. The congenitally missing maxillary lateral incisor. Part 1: Esthetic judgment of treatment options. *World J Orthod* 2005; 6:369-375.
- Armbruster PC, Gardiner DM, Whitley JB, Flerra J. The congenitally missing maxillary lateral incisor. Part 2: Assessing dentist's preferences for treatment. *World J Orthod* 2005; 6:376-381.
- Bernard JP, Schatz JP, Christou P, Belser U, Kiliaridis S. Long-term vertical changes of the anterior maxillary teeth adjacent to single implants in young and mature

- adults. A retrospective study. *J Clin Periodontol* 2004; 31:1024-1028.
- Bishop K, Addy L, Knox J. Modern restorative management of patients with congenitally missing teeth: 3. Conventional και restorative options και considerations. *Dent Update* 2007; 34:30-38.
- Bishop K, Addy L, Knox J. Modern restorative management of patients with congenitally missing teeth: 4. The role of implants. *Dent Update* 2007; 34:79-84.
- Buser D, Martin W, Belser UC. Optimizing esthetics for implant restorations in the anterior maxilla: anatomic και surgical considerations. *Int J Oral Maxillofac Implants.* 2004; 19 Suppl:43-61.
- Chiapasco M, Casentini P, Zaniboni M. Bone augmentation procedures in implant dentistry. *Int J Oral Maxillofac Implants.* 2009; 24 Suppl:237-259.
- Czochrowska EM, Stenvik A, Album B, Zachrisson BU. Autotransplantation of premolars to replace maxillary incisors. A comparison with natural incisors. *Am J Orthod Dentofacial Orthop* 2000; 118:592-600.
- Czochrowska EM, Stenvik A, Bjercke B, Zachrisson BU. Outcome of tooth transplantation: survival και success rates 17-41 years posttreatment. *Am J Orthod Dentofacial Orthop* 2002; 121:110-119.
- Czochrowska EM, Stenvik A, Zachrisson BU. The esthetic outcome of autotransplanted premolars replacing maxillary incisors. *Dent Traumatol* 2002; 18:237-245.
- Kern M. Clinical long-term survival of two-retainer και single-retainer all-ceramic resin-bonded fixed partial dentures. *Quintessence Int.* 2005 Feb; 36(2):141-147.
- Kinzer GA, Kokich VO. Managing congenitally missing incisors. Part II: Tooth-supported restorations. *J Esthet Restor Dent.* 2005; 17:76-84.
- Kokich VG. Maxillary lateral incisor implants: planning with the aid of orthodontics. *Int J Oral Maxillofac Surg* 2004; 62:48-56.
- Magne P, Magne M, Belser UC. Adhesive restorations, centric relation, και the Dahl principle: minimally invasive approaches to localized anterior tooth erosion. *Eur J Esthet Dent.* 2007; 2(3):260-73.
- McNeill RW, Joondeph DR. Congenitally absent maxillary lateral incisors: treatment planning considerations. *Angle Orthod.* 1973; 43(1):24-29.
- Nordquist GG, McNeill RW. Orthodontic vs. restorative treatment of the congenitally absent lateral incisor-long term periodontal και occlusal evaluation. *J Periodontol.* 1975 Mar; 46(3):139-143.
- Odman J, Grondahl K, Lekholm U, Thilander B. The effect of osseointegrated implants on the dento-alveolar development. A clinical και radiographic study in growing pigs. *Eur J Orthod* 1991; 13(4):279-286.
- Rosa M, Zachrisson BU. Integrating esthetic dentistry και space closure in patients with missing maxillary lateral incisors. *J Clin Orthod* 2001; 35:221-234.
- Sabri R. Management of missing maxillary lateral incisors. *J Am Dent Assoc* 1999; 130:80-84.
- Savarrio L, McIntyre GT. To open or to close space-That is the missing lateral incisor question. *Dent Update* 2005; 32:16-25.
- Slagsvold O, Bjercke B. Applicability of autotransplantation in cases of missing upper anterior teeth. *Am J Orthod.* 1978 Oct; 74(4):410-421.
- Thilander B, Ödman J, Jemt T. Single implants in the upper incisor region και their relationship to the adjacent teeth; an 8- year follow-up study. *Clin Oral Impl Res* 1999; 10:346-355.
- Thilander B. Orthodontic space closure versus implant placement in subjects with missing teeth. *J Oral Rehabil* 2008; 35 Suppl 1:64-71.
- Verzijden CW, Creugers NH, van't Hof MA. Treatment times for posterior resin-bonded bridges. *Community Dent Oral Epidemiol.* 1990 Dec; 18(6):304-308.

